

Accurate Reconstruction of Mandibular Defects With Vascularized Bone Flaps Through Utilization of Mandible Space-Retention Guides

Chengyi Wang, DDS,* Zhaoqiang Meng, BDS,† Bimeng Jie, DDS,* Ruiliu Li, DDS,*
Yang He, MD, DDS,* and Mingming Xu, DDS‡

Purpose: Comprehensive evaluation of the effects of using computer-aided design and space retention guide technology to reconstruct mandibular defects using vascularized autogenous bone flaps.

Method: This study included 8 patients who received autogenous bone flaps (2 cases of vascularized fibula flaps and 6 cases of vascularized iliac flaps) for mandibular defect reconstruction at Peking University School and Hospital of Stomatology, from July 2018 to May 2021. All patients received digital surgery planning, computer aided design/computer aided manufacture, surgical guide technique for the removal of diseased bone segments, as well as vascularized fibular flap/iliac flap reconstruction. Three-dimensional deviations were analyzed after the operation.

Result: The mandibular defects of all 8 patients were successfully reconstructed using the vascularized fibular flap/iliac bone flap. There were no serious complications at either the donor site or recipient site during our follow-up. The average three-dimensional deviation of all 8 patients was 1.92 mm, based on comparisons of preoperative design and actual postoperative computed tomography.

Conclusion: Utilizing computer aided design/computer aided manufacture, we designed a new mandibular space-retention guide,

which can accurately translate the preoperative digital design plan to real-time surgery with satisfactory accuracy and efficacy.

Key Words: Digital design, mandibular defect reconstruction, mandibular space guide, osteotomy guide plate, vascularized autologous bone flap

(*J Craniofac Surg* 2022;33: 1484–1487)

Functional reconstruction of mandibular defects has become a common surgical procedure that is performed routinely by oral and maxillofacial surgeons. Virtual Surgical Planning has greatly improved the accuracy of reconstructive surgery. At present, computer-assisted navigation and digital surgical guides (ISGs) are the major modes for translating Virtual Surgical Planning into clinical practice.

However, intraoperative navigations have limited applications in mandibular reconstruction due to complicated preoperative design and deviation in the guidance of the mandibular area during surgical operation. The ISGs previously reported were mainly used to define the osteotomy line. Both methods do not provide ideal solutions to control the position of the residual condyle or ascending bone segment, particularly for large-scale mandible defects.

In this study, we developed a novel method that applies space-retention guides to complete the reconstruction of large-scale mandible defects. We also evaluated the accuracy of this new method.

METHODS

The study population was comprised of patients who had received vascularized bone flaps for mandibular reconstruction at Peking University School and Hospital of Stomatology, from July 2018 to May 2021. The treatment procedure for all patients followed 4 basic processes: preoperative virtual design; preoperative guide design and manufacturing; surgery guided by space-retention guide; postoperative evaluation and follow-up. This study was approved by the ethics committee of our hospital (PKUSSIRB-202055065), and was carried out in accordance with the principles of the declaration of Helsinki. The clinical characteristics of the enrolled patients are presented in Table 1 (as shown in Supplementary Digital Content, Table 1, <http://links.lww.com/SCS/D618>).

Preoperative Virtual Design

We collected the spiral computed tomography (CT) digital imaging and communications in medicine data of the patient's maxillofacial region and donor site, and then imported the maxillofacial data into the digital software ProPlan CMF 3.0 (Leuven, Belgium) to complete the three-dimensional (3D) reconstruction.

From the *Department of Oral and Maxillofacial Surgery; †Special Dental Care Clinic; and ‡Department of Geriatric Dentistry, Peking University School and Hospital of Stomatology, Beijing, China.

Received October 26, 2021.

Accepted for publication November 4, 2021.

Address correspondence and reprint requests to Yang He, MD, DDS, Department of Oral and Maxillofacial Surgery, Peking University School and Hospital of Stomatology, No 22 Zhongguancun South Avenue, Beijing 100081, China;

E-mail: fridaydust1983@163.com; Mingming Xu, DDS, Department of Geriatric Dentistry, Peking University School and Hospital of Stomatology, No 22 Zhongguancun South Avenue, Beijing 100081, China; E-mail: anniemmx@126.com

CW and ZM contributed to the work equally and should be regarded as co-first authors. YH and MX contributed to the work equally and should be regarded as co-corresponding authors

This work was supported by National Science and Technology basic resources project (2018FY101004). The funding agencies had no role in the study design, clinical procedures, analysis of the results, or preparation of the manuscript.

The authors report no conflicts of interest.

Supplemental digital contents are available for this article. Direct URL citations appear in the printed text and are provided in the HTML and PDF versions of this article on the journal's Web site (www.jcraniofacialsurgery.com).

Copyright © 2022 by Mutaz B. Habal, MD

ISSN: 1049-2275

DOI: 10.1097/SCS.00000000000008408

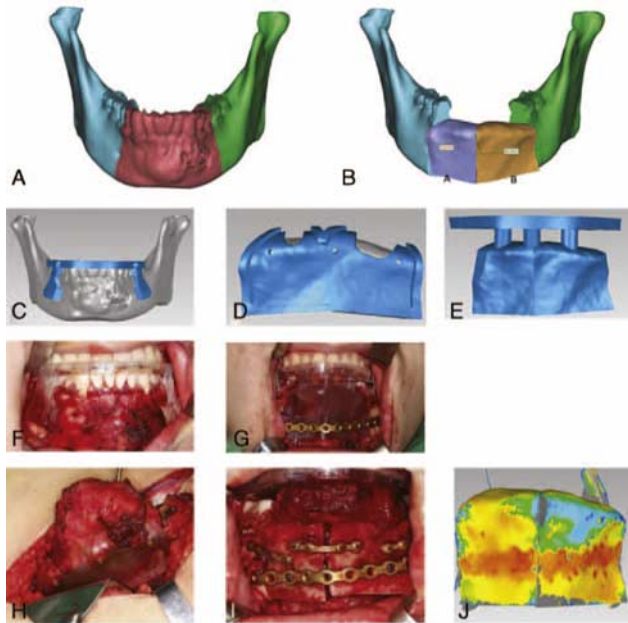


FIGURE 1. A 28-year-old male patient. The pathological results showed ossified fibroma in the front of the mandible. A, Design of virtual osteotomy using digital technology. B, Design of virtual vascularized iliac bone flap reconstruction. C, Design of mandibular osteotomy guide. D, Design of iliac osteotomy guide. E, Design of mandibular space-retention guide. F, Intraoperative-mandibular osteotomy guide was installed. G, The installation of the positioning guide was completed. H, The installation of the iliac osteotomy guide was completed. I, The vascularized iliac bone flap was in place, and the titanium plate was fixed with titanium nails. J, Postoperative three-dimensional chromatographic analysis and evaluation of mandibular reconstruction accuracy.

For patients diagnosed with tumor, we designed the osteotomy line according to the tumor resection boundary and completed the simulated osteotomy. Then, based on published methodologies,¹ mirror technology was used for unilateral defects reconstruction, while the database was used for cross-midline defects. The type of bone flap was determined according to the length of the defect area, and the bearing capacity of the bone flap.^{2,3} Then we imported the data of the donor site, and designed the repair plan according to the shape of the reference data model, taking into account the occlusal distance, and utilizing the design file and the stereolithography (STL) model (Fig. 1A and B).

For patients with secondary trauma repair, we simulated the debridement and defined the defect after debridement. After obtaining the reference data according to the above method, we adjusted the position of the condyle and ascending ramus segment according to the reference data, before proceeding to the subsequent design. The design method is the same as described above (Fig. 2C).

Design and Manufacture of Mandibular Space-Retention Guide

We imported the reconstruction plan file into the software Chinese craniomaxillofacial surgery planning software Plan V1.0 (Bettercom, Peking University, China) to design the surgical guide. First, we designed a tumor osteotomy guide to indicate the tumor osteotomy line. This usually extends and fits the lower edge of the mandible and the buccal surface outside the tumor osteotomy line. Two holes are made on each side for intraoperative use (Fig. 1C). Then we designed the mandibular space-retention guide. The main

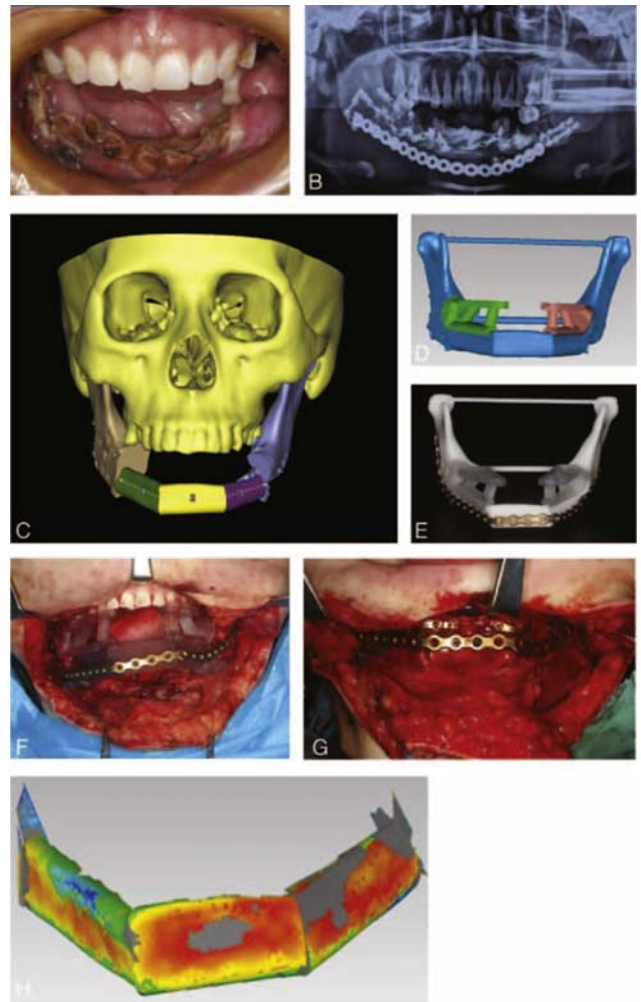


FIGURE 2. A, B, A 17-year-old female patient with multiple mandibular fractures after open reduction and internal fixation. Partial necrosis of the mandible occurred, and the wound continued to ulcerate with accumulation of pus. C, Virtual debridement and segmentation of the mandible using digital technology, osteotomy, and vascularized free fibular flap reconstruction. D, E, Design of tooth-supported mandibular space-retention guide and precurved reconstruction titanium plate. F, Occupational guide plate placement is completed. G, Fibula flap shaping is completed. H, Three-dimensional chromatographic analysis after surgery showed the accuracy of the mandibular restoration.

body of the space-retention guide plate is the shape of the bone flap, and then the extended wings were designed at the proximal and distal ends to fit the lower edge and buccal surface of the mandible (Fig. 1E). If the patient has a mandibular full dentition defect, the intermaxillary space-retention guide is designed to determine the intermaxillary distance (Fig. 2D). Finally, the osteotomy guide of the donor site is designed to indicate the osteotomy at the donor site.

The virtually designed guide and mandible model were fabricated through three-dimensional printing technology. The reconstruction titanium plate was prebent according to the 3D model before surgery (Fig. 2E).

Surgery Guided by Space-Retention Guide

For tumor resection patients, we placed an osteotomy guide plate and completed the osteotomy according to the position of the osteotomy line. For trauma patients, we followed the os-

teotomy guide to debride the wound, form a defect, and then ligate the jaw. For patients without dentition, we placed an occlusal guide to indicate the distance between the jaws (Fig. 2F).

Resection or debridement was performed according to the osteotomy line on the guide. Then the defect occupying guide was placed on the defect part to simulate the reconstruction. Both ends were fixed on the mandible through the extension wing, to make sure that the residual mandibular segments were fixed in a unique position. After that, the reconstruction titanium plate was fixed with no less than 3 screws on each side. At the same time, we removed the occupying guide plate so that the 2 ends of the mandible defect were fixed (as shown in Figure 1G, 2F).

Under the guidance of the osteotomy guide plate, the iliac bone flap or fibula flap was prepared, and then the bone flap was transplanted to the defect area. After the vascular anastomosis was completed, the bone flap was fixed on the reconstruction titanium plate (Figure 1I, 2I).

Postoperative Evaluation and Follow-Up

One week after the operation, we took the patients' maxillofacial spiral CT again, and imported the postoperative CT data into the ProPlan CMF 3.0 (Leuven, Belgium) software, and obtained the mandible STL file after 3D reconstruction and segmentation. The postoperative STL file and the preoperative virtual design file were then imported into the Geomagic Studio 2014 software, and 3D deviation analysis was used to evaluate the error between the postoperative bone flap repair position and the preoperative virtual design (as shown in Figure 1I, 2J).

RESULTS

General Information

Eight patients were included in this study. Six patients were males and 2 were females, ranging in age from 14 to 60 years old, with a median age of 30 years. Five mandibular defects resulted from trauma, while 3 resulted from tumor resection. There were 2 vascularized fibular flaps and 6 vascularized iliac flaps. The basic clinical characteristics of the patients are shown in Table 1 (as shown in Supplementary Digital Content, Table 1, <http://links.lww.com/SCS/D618>).

Postoperative Follow-Up and Complications

The operation was completed smoothly with the help of surgical guides. All flaps survived after surgery, and there were no postoperative complications, such as wound infection and exposure or breakage of the titanium plate. During the follow-up period, there were no serious donor site complications such as hernias, fractures, and gait disturbance. All patients were satisfied with the results of the operation.

Accuracy of Surgical Guides

We compared the 3D deviations between the preoperative design model and the postoperative reconstruction model.

Among the 3D deviations, the overall deviation of the mandible ranged from -1.7765 to 1.7565 mm, with an average of 1.9029 ± 1.9163 mm (as shown in Supplementary Digital Content, Table 1, <http://links.lww.com/SCS/D618>). The contour of the grafted bone was similar to the contour of the designed mandible before surgery. The postoperative CT scan showed that the mandible was symmetrical and that the position of the condyle was basically correct.

DISCUSSION

Mandibular resection defects caused by tumors, trauma, and inflammation can cause functional and aesthetic deficits. Utilization of fibula and iliac flaps (DCIA) as autogenic grafts for mandibular reconstruction has become routine and commonplace in clinical practice.⁴⁻⁷ However, the mandible has a more complicated curved shape, which makes it difficult to be fully restored. The remaining segments are unstable, particularly with respect to RB or cross-midline defects.⁸ Therefore, accurate mandible reconstruction is still a major challenge for surgeons.

In recent years, several studies have shown that the synergistic application of computer design, 3D printing technology, and surgical navigation can make surgical planning and implementation faster and more accurate.⁸⁻¹⁰ Yu et al¹¹ introduced a new method to improve the accuracy of mandibular reconstruction with vascularized iliac crest flaps using computer-assisted techniques. They performed mandibular resection under the guidance of an intra-operative CANS, and harvested the iliac flap under the guidance of an ISG. The prebent titanium plate is placed and fixed with the guidance of CANS. However, intraoperative CANS also have several limitations. First, intraoperative navigation technology matches the preoperative digital design plan with the patient's craniomaxillofacial area through landmark registration or surface registration, so that the surgeon can intuitively verify the accuracy of the operation. When using surface registration, the registration area is located in the upper middle area of the face. The mandible is far away from the registration area, and therefore the accuracy is poor.¹² Second, different from the structure of the maxilla, the mandible is movable in three-dimensional space, and the proximal segment of the mandible after intraoperative osteotomy is unstable. Therefore, intermaxillary fixation (IMF) has to be applied to stabilize the position of the mandible, and the navigation system can then be used to guide the osteotomy and reconstruction process.^{8,9,13,14} The method of using titanium nails for IMF is more cumbersome and increases the trauma of the nonsurgical area. Third, for large-scale mandible defect that involves the mandibular body and ramus, or that which crosses the midline, the positions of the remaining mandible are not unique even with IMF use.¹¹

Hence, there are studies that have demonstrated that the combination of navigation and computer aided design/computer aided manufacture (CAD/CAM) technology improves the surgical procedure, which assists in resolving the difficulties in reference point selection during the mandibular reconstruction process, and improves accuracy of the reconstruction.^{15,16,17} Three-dimensional-printed surgical guides based on CAD/CAM technology are widely used in mandibular osteotomy, vascularized bone flap harvesting, and shaping. It can reproduce the preoperative virtual surgery plan during the operation.¹⁸ Zheng et al separated the 3D mandible model into 2 parts: the reconstruction segment and the remaining mandible. During surgery, the reconstructed segment with the affixed reconstruction plate is transferred to the mandibular defect to assist titanium plate placement and fixation. This method provides a viable option to stabilize the mandible position, which is applicable to benign mandibular tumors. However, for large-scale mandible defects secondary to trauma or inflammation, this approach does not work.

In this study, with the help of preoperative computer design and space-retention guides, mandible osteotomy was performed and the vascularized bone flap was obtained. The 3D-printed space guides were used to occupy the mandibular defect position in 3 dimensions and restore the spatial position of the re-

maining segments. The curved reconstruction plate fixes the mandibular segments, and places the shaped bone flaps on the defect for fixation. We obtained a 3D deviation of 1.9029 ± 1.9163 mm on average, which is better than the results of Yu et al.¹¹ In addition, the operation time was effectively shortened compared with traditional methods.

This method is simpler, more convenient, and efficient than using navigation, which needs repeated adjustments and confirmation of the reference point during the operation. To make more accurate and effective guide plates, it is necessary to deepen collaboration with engineers to achieve continuous improvements. For example, we designed a marker model on the bone surface as a fixed point mark in the preoperative design to quickly locate the guide template. In addition, it is necessary to reserve 0.5 mm of osteotomy loss on both the sides of the saw line, which can partially offset the osteotomy. These can overcome the problem of bone loss and provide higher accuracy.

In summary, this study provides preliminary data that demonstrates the advantages of space-retention guides in mandibular reconstruction. However, a larger sample size and longer follow-up time are needed to further validate our findings.

CONCLUSION

By utilizing CAD/CAM, a novel mandibular space-retention guide can accurately translate the preoperative digital design to real-time surgery with satisfactory accuracy and efficacy.

REFERENCES

- Jie B, Yao B, Li R, et al. Post-traumatic maxillofacial reconstruction with vascularized flaps and digital techniques: 10-year experience. *Int J Oral Maxillofac Surg* 2020;49:1408–1415
- Vittayakittipong P, Jarudejkajon J, Kirirat P, et al. Feasibility of the vascularized fibula bone graft for reconstruction of the mandible: a cadaveric study. *Int J Oral Maxillofac Surg* 2016;45:960–963
- Brown JS, Barry C, Ho M, et al. A new classification for mandibular defects after oncological resection. *Lancet Oncol* 2016;17:e23–e30
- Farwell DG, Futran ND. Oromandibular reconstruction. *Facial Plast Surg* 2000;16:115–126
- Modabber A, Ayoub N, Mohlhenrich SC, et al. The accuracy of computer-assisted primary mandibular reconstruction with vascularized bone flaps: iliac crest bone flap versus osteomyocutaneous fibula flap. *Med Devices (Auckl)* 2014;7:211–217
- Modabber A, Mohlhenrich SC, Ayoub N, et al. Computer-aided mandibular reconstruction with vascularized iliac crest bone flap and simultaneous implant surgery. *J Oral Implantol* 2015;41:e189–e194
- Zheng L, Lv X, Zhang J, et al. Translating computer-aided design and surgical planning into successful mandibular reconstruction using a vascularized iliac crest flap. *J Oral Maxillofac Surg* 2018;76:886–893
- Hirsch DL, Garfein ES, Christensen AM, et al. Use of computer-aided design and computer-aided manufacturing to produce orthognathically ideal surgical outcomes: a paradigm shift in head and neck reconstruction. *J Oral Maxillofac Surg* 2009;67:2115–2122
- Roser SM, Ramachandra S, Blair H, et al. The accuracy of virtual surgical planning in free fibula mandibular reconstruction: comparison of planned and final results. *J Oral Maxillofac Surg* 2010;68:2824
- Efanov JI, Roy AA, Huang KN, et al. Virtual surgical planning: the pearls and pit falls. *Plast Reconstr Surg Glob Open* 2018;6:e1443
- Yu Y, Zhang WB, Wang Y, et al. A revised approach for mandibular reconstruction with the vascularized iliac crest flap using virtual surgical planning and surgical navigation. *J Oral Maxillofac Surg* 2016;74:1285.e1281–1285.e1211
- Sun J. Mandibular reconstruction assisted by virtual surgery planning and intraoperative navigation: from precision to minimally invasive. *Chinese J Recons Surg* 2018;32:821–826
- Li Y, Shao Z, Zhu Y, et al. Virtual surgical planning for successful second-stage mandibular defect reconstruction using vascularized iliac crest bone flap: a valid and reliable method. *Ann Plast Surg* 2020;84:183–187
- Zheng L, Lv X, Zhang J, et al. Translating computer-aided design and surgical planning into successful mandibular reconstruction using a vascularized iliac-crest flap. *J Oral Maxillofac Surg* 2018;76:886–893
- Juergens P, Klug C, Krol Z, et al. Navigation-guided harvesting of autologous iliac crest graft for mandibular reconstruction. *J Oral Maxillofac Surg* 2011;69:2915–2923
- Zhang L, Liu Z, Li B. Evaluation of computer-assisted mandibular reconstruction with vascularized fibular flap compared to conventional surgery. *Oral Surg Oral Med Oral Pathol Oral Radiol* 2016;121:139–148
- Wu J, Sun J, Shen SG, et al. Computer-assisted navigation: its role in intraoperatively accurate mandibular reconstruction. *Oral Surg Oral Med Oral Pathol Oral Radiol* 2016;122:134–142
- Foley BD, Thayer WP, Honeybrook A, et al. Mandibular Reconstruction using computer-aided design and computer-aided manufacturing: an analysis of surgical results. *J Oral Maxillofac Surg* 2013;71:e111–e119