



Available online at www.sciencedirect.com

ScienceDirect

journal homepage: www.e-jds.com



Short Communication

A digitally designed and 3D printed individual tooth tray for taking subgingival impression of complete crown preparation

Xiaoxiang Xu ^a, Qiufei Xie ^a, Lei Zhang ^a, Yijiao Zhao ^b, Ye Cao ^{a*}

^a Department of Prosthodontics, Peking University School and Hospital of Stomatology & National Center of Stomatology & National Clinical Research Center for Oral Diseases & National Engineering Laboratory for Digital and Material Technology of Stomatology & Beijing Key Laboratory of Digital Stomatology & Research Center of Engineering and Technology for Computerized Dentistry Ministry of Health & NMPA Key Laboratory for Dental Materials, Beijing, PR China

^b Center of Digital Dentistry, Peking University School and Hospital of Stomatology & National Center of Stomatology & National Clinical Research Center for Oral Diseases & National Engineering Laboratory for Digital and Material Technology of Stomatology & Beijing Key Laboratory of Digital Stomatology & Research Center of Engineering and Technology for Computerized Dentistry Ministry of Health & NMPA Key Laboratory for Dental Materials, Beijing, PR China

Received 30 May 2021; Final revision received 2 June 2021

Available online 23 June 2021

KEYWORDS

3D printing;
Computer aided design;
Impression;
Subgingival margin;
Tray

Abstract A digital technique for designing and fabricating an individual tooth tray used for taking subgingival impression of complete crown preparation was described. The digital model of required dentition region was obtained before performing crown preparation. An individual tooth tray with retention attachments was designed and printed with plastic material. After conducting crown preparation, the individual tooth tray loaded with the final impression material was placed onto the abutment to deliver the impression material subgingivally. A final overall impression was made with full arch stock tray to pick up the individual tooth tray with the accurate impression of abutment.

© 2021 Association for Dental Sciences of the Republic of China. Publishing services by Elsevier B.V. This is an open access article under the CC BY-NC-ND license (<http://creativecommons.org/licenses/by-nc-nd/4.0/>).

* Corresponding author. Department of Prosthodontics, Peking University School and Hospital of Stomatology, No.22 Zhong Guan Cun South Avenue, Haidian District, Beijing, 100081, PR China.

E-mail address: ye.cao@bjmu.edu.cn (Y. Cao).

Accurate impressions are essential for the quality and longevity of fixed restorations. In some clinical cases, a subgingival finishing line should be prepared on the abutment, including the prosthetic treatment for discolored anterior teeth, cervical tooth defect caused by decay, trauma, or abrasion. The reproduction of subgingival anatomy is the most challenging part for impression taking in these conditions, even in the present time of digital dentistry. Applying retraction cord or paste is the commonly used method to displace the gingiva tissue and expose the subgingival margin.¹ However, the gingiva will start to relapse once these materials are removed. This may negatively impact the flow of impression material into gingival sulcus, or the optical collection by an intraoral scanner, then lead to a dissatisfactory replication effect of the subgingival structure. For cases with a deep subgingival finishing line, the retraction cord placed in the gingival crevice is inadequate to deflect and support the top part of free gingiva. The gingiva crest will collapse onto the prepared margin and result in a failed subgingival registration. Besides, the placement of retraction cord is arduous, and may cause patient discomfort as well as soft tissue injury that can induce gingiva recession especially in thin biotype cases.²

An alternative cordless technique for subgingival impression using an acrylic shell was described in 1965 by Cannistraci.³ This technique involved the development of a special form of small-sized tray filled with impression material, which can displace the gingiva by its insertion, meanwhile deliver the impression material into the sulcus. By this way, ideal subgingival registration can be readily fulfilled without the application of retraction material in the first place. Besides, the least traumatic reaction of gingival tissue was noted by this method without any accompanying trauma and recession caused by the retraction cord.⁴ Since that time, other forms of techniques with the similar principle have involved, including aluminum shell,⁵ copper band,⁶ resin copings,⁷ preformed crown shells,⁸ or acrylic thimble.⁹ Although these techniques are able to achieve better outcomes for subgingival impression, the fabrication and adjustment of these specific trays will cost considerable chairside time. Sometimes, additional appointment is required for the preparation of these trays. This disadvantage has restricted the popularization of these cordless techniques.

With advancement of digital technology, the application of digital scanning, computer aided design (CAD) and manufacture have provided remarkable convenience, accuracy, and efficiency in prosthodontics. This paper described a digital technique to design and fabricate an individual tooth tray, which could be used to make high-quality subgingival impression for crown preparation in a reliable and time-saving way.

Technique

To introduce this technique, a patient who had the plan to make full crown restorations for her fractured bilateral upper central incisors was presented (Fig. 1A).

1. The digital model of the required dentition region was obtained before the crown preparation (Fig. 1B). This could be achieved directly by intraoral scanning, or a traditional way through taking a preliminary impression and pouring the diagnostic cast, then scanning the model. Generally, making the diagnostic cast is a routine step for prosthetic treatment.
2. The digital data was imported to a dental CAD software (Dental system, 3 shape, Copenhagen, Denmark). The design module of the temporary crown was used. The margin line was placed precisely along the periphery of the cervical area of the abutment tooth, and not beyond the gingiva crest. The margin line at the proximal side could be set by simulated erasing the neighbor tooth (Fig. 1C).
3. The contour of individual tooth tray was designed by adjusting the original shape of the abutment tooth, or introducing a new tooth contour preinstalled in the database in case of severe tooth defect. The labial and palatal contour were enlarged to obtain sufficient inner space for impression material. Ensure no contact with the adjacent tooth at the proximal surface. The retention attachments were added at labial and palatal surface (Fig. 1D and E). The thickness of margin was set with 0.15 mm and the body of individual tooth tray with 0.4 mm.
4. The designed data was sent to a 3D printer (Objet 260, Stratasys, Eden Prairie, MN, USA). The individual tooth tray was printed with Polyjet plastic dental material (MED 690, Stratasys) (Fig. 1F).
5. The definitive complete crown preparation procedure was performed. The individual tooth tray was tried in on the prepared abutments (Fig. 2A). Generally, no adjustment or just little trim at the proximal margin would be required for fully seating the tray. Then, try in the complete arch stock tray and ensure no interference between the individual tooth tray and the stock tray.
6. The final impression material was loaded (polyether, 3 M ESPE, St Paul, MN, USA) into the individual tooth tray gently. Avoid air bubbles formation during the procedure. The surface of abutment teeth was cleaned and dried. Optionally, the impression material was injected around the prepared teeth. Then, the individual tray filled with impression was placed on the abutment teeth slowly. The insertion force should be gentle not to cause tray deformation or gingival injury. The surplus impression material would overflow from the gingival margin, further deflect the gingiva toward the desired direction (Fig. 2B).
7. The individual tooth tray was kept stable till the impression set. The routine procedure for complete arch impression taking with stock tray was performed. The final impression material was injected into the spaces at the proximal side of abutments and the undercut areas of the individual tray before placing the overall stock tray to avoid voids in the impression. The end result was an accurate final impression of the abutment teeth as part of a complete arch impression (Fig. 2C and D).
8. Fabricate and insert the definitive all-ceramic complete crowns (Fig. 2E and F).

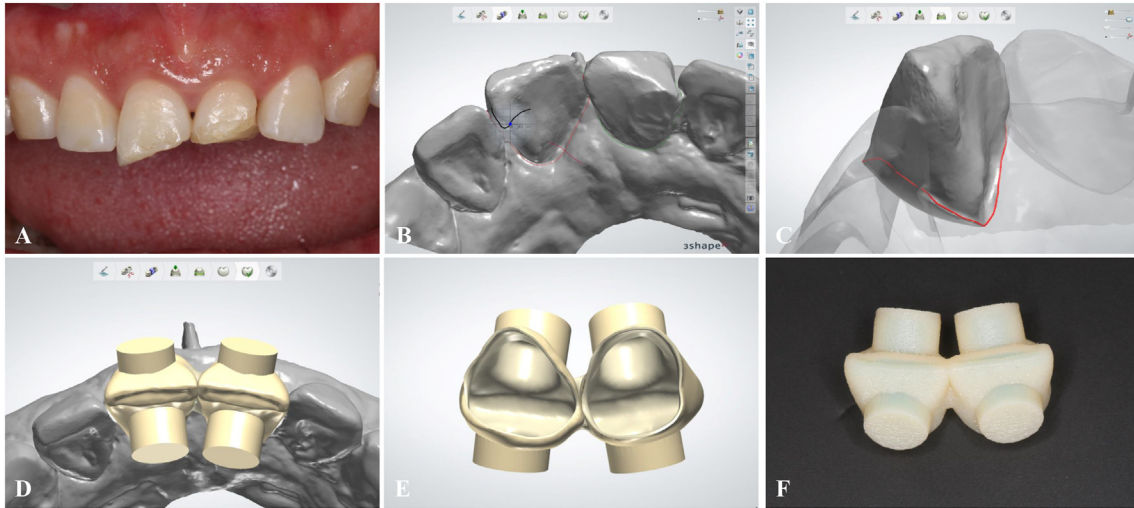


Figure 1 The computer-aided design of individual tooth tray. (A) The fractured bilateral upper central incisors have received root canal therapy for making full crown restorations. (B) The digital model of the anterior dental arch region. Note the subgingival defect of the palatal cervical part of the right upper central incisor. (C) The placement of the marge line on the abutment tooth. (D) The designed contour of individual tooth tray with retention attachments from occlusal view. (E) The designed contour of individual tooth tray with retention attachments from bottom view. (F) The 3D printed individual tooth tray.

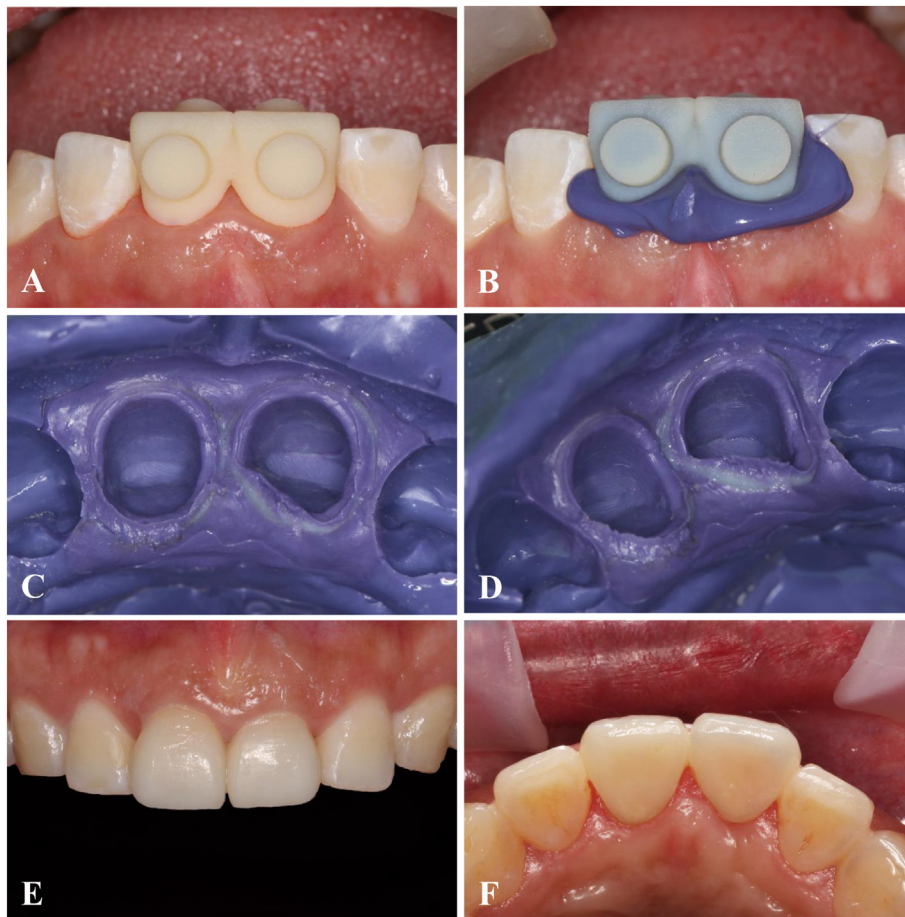


Figure 2 The impression taking procedure with individual tooth tray. (A) Try in the individual tooth tray after crown preparation. (B) Insertion the individual tooth tray with final impression material. (C) and (D) The final impression of abutment teeth with intact intracrevicular extension to accurately reproduce the subgingival margin. (E) and (F) The final restorations.

Discussion

The margin line of individual tooth tray should be precisely placed within the range beyond the cervical periphery of abutment and not cross the gingiva crest, in order to displace the gingiva tissue to expose the cervical margin and avoid the interference from the abutment while inserting. This is the key factor impacting the effectiveness of this technique. The traditional way to achieve this requirement is firstly capture the shape of prepared tooth and around soft tissue through relining approach, then remove part of the relining material to obtain the impression space and eliminate the insertion interference. These operations usually take considerable chairside time. With the advantage of digital technology, the margin position of individual tooth tray can be facilitated in the CAD procedure with the aid of zoom-in view and sectional display, then accurately fabricated by 3D printing technology. This will save the precious time for clinical adjustment required in the traditional relining technique. Notably, this technique allows for the completion of individual tooth tray during the case analysis stage before conducting the crown preparation. No additional appointment for preparing the individual tooth tray will be required.

One problem may be concerned is the marginal accuracy at proximal side of individual tooth tray. This technique involves stimulated removal of neighbor teeth and exposure of proximal surface of abutment tooth. For beginners, the proximal margin line can be placed a little apically in order to facilitate further adjustment in clinic. The amount of chairside trim will be small and will not cost too much time. With increased experience, the proximal margin will be properly placed with little or no adjustment required. Another problem may be concerned is the possibility that the thin impression inside the individual tooth tray may be separated from the tray during the withdrawal of the final impression. The retention form provided by the attachments will help to prevent the separation of inner impression. Additionally, tray adhesion for the final impression can be applied on the external and internal surface of the individual tooth tray to provide more retentive effect.¹⁰ Based on the authors' experience, using tray adhesion is not mandatory for normal crown preparation without obvious undercut. The last problem may be concerned is the increased risk of die breakage due to the thin impression and rigidity of tray material around the abutment. To overcome this problem, we used uniform thin (0.4 mm) plastic material to print the individual tooth tray, which will end up with certain flexible mechanical property rather than complete rigidity. So the risk of cast fracture can be reduced to a minimum, meanwhile the complete arch stock tray can provide the required rigidity as usual to ensure the dimensional accuracy for final overall impression. Besides, the definitive impression can be scanned directly without pouring the cast, and transfer to the digital procedures instead.

In conclusion, this article described a novel digital technique for the design and fabrication of an individual tooth tray, which can be prepared before crown preparation, and used for efficiently and accurately taking subgingival impression of complete crown preparations, without the requirement of time-consuming chairside adjustment and gingival displacement with retraction cords. This technique can be used in traditional prosthodontic procedures, as well as those combined with digital technology.

Declaration of competing interest

The authors have no conflicts of interest relevant to this article.

Acknowledgments

The authors thank Lu Jia from Dental Laboratory of Peking University School and Hospital of Stomatology for technical assistance. This work is supported by National Natural Science Foundation of China (81800998) and Program for New Clinical Techniques and Therapies of Peking University School and Hospital of Stomatology (PKUSSNCT-19B14 and PKUSSNCT-14B04).

References

- Huang C, Somar M, Li K, et al. Efficiency of cordless versus cord techniques of gingival retraction: a systematic review. *J Prosthodont* 2017;26:177–85.
- Einarsdottir ER, Lang NP, Aspelund T, et al. A multicenter randomized, controlled clinical trial comparing the use of displacement cords, an aluminum chloride paste, and a combination of paste and cords for tissue displacement. *J Prosthet Dent* 2018;119:82–8.
- Cannistraci AJ. A new approach to impression taking for crown and bridge. *Dent Clin* 1965;29:33–42.
- Ruel J, Schuessler PJ, Malament K, et al. Effect of retraction procedures on the periodontium in humans. *J Prosthet Dent* 1980;44:508–15.
- LaForgia A. Cordless tissue retraction for impressions for fixed prosthesis. *J Prosthet Dent* 1967;17:379–86.
- Kimmelman BB, Lerman H. Impressions of single preparations using a copper band-shell. *J Prosthet Dent* 1971;26:154–8.
- Hoffman JM. Nontraumatic final impressions for fixed partial dentures. *J Prosthodont* 1992;1:61–4.
- Dimashkieh MR, Morgano SM. A procedure for making fixed prosthodontic impressions with the use of preformed crown shells. *J Prosthet Dent* 1995;73:95–6.
- Matsumoto W, de Almeida Antunes RP, Fernandes RM, et al. Shell tray impression: a technique modification. *J Dent Pub H* 2018;9:8–16.
- Xu Y, Unkovskiy A, Klaue F, et al. Compatibility of a silicone impression/adhesive system to FDM-printed tray materials-A laboratory peel-off study. *Materials* 2018;11.