

Dental Implant Rehabilitation After Jaw Reconstruction Assisted by Virtual Surgical Planning

Houwei Zhu, DDS¹/Lei Zhang, DDS, PhD²/Zhigang Cai, DDS, DMD³/Xiaofeng Shan, DDS, MD²

Purpose: To evaluate effects of preoperative virtual planning and jaw reconstruction guided by dental implant rehabilitation on dental prosthesis rehabilitation after jaw reconstruction. **Materials and Methods:** Patients indicated for segmental jaw resection and who agreed to receive jaw reconstruction procedures were enrolled in the study. Appropriate surgical procedures were determined by a maxillofacial surgeon and a prosthodontist before surgery. The virtual design was created according to preoperative computed tomography. Patients were divided into navigation and non-navigation groups. Implant surgery was performed 6 months after reconstruction surgery. After treatment completion, factors such as survival rate of implants, site of reconstruction, type of graft, and type of prosthesis were compared. **Results:** In total, 29 patients were included in the study, with 16 patients in the non-navigation group and 13 in the navigation group. A total of 101 implants were inserted, and the implant success rate was 98.02% (2 implants extracted due to peri-implantitis). All patients received prosthetic treatment. Of the 13 navigation group patients, 9 received fixed implant-supported prostheses, whereas the other 4 received removable dentures. Of the 16 non-navigation group patients, 9 eventually received fixed implant-supported prostheses and 7 received removable dentures. There were no significant intergroup differences in terms of prosthesis type ($P = .702$). However, the proportion of fixed implant-supported prostheses in the navigation group was higher compared with the non-navigation group. **Conclusion:** Preoperative virtual planning and dental implant rehabilitation-guided jaw reconstruction through preoperative designing can provide a good opportunity to achieve high rates of implant success and dental rehabilitation. This method can also benefit fixed implant-supported prosthetic restorations. Moreover, the use of navigation after virtual planning has no effect on the type of prosthetic reconstruction. *INT J ORAL MAXILLOFAC IMPLANTS* 2019;34:XXX-XXX. doi: 10.11607/jomi.7278

Keywords: dental implants, dental rehabilitation, jaw reconstruction, surgical navigation, virtual planning

¹Resident, Department of Oral and Maxillofacial Surgery, Peking University School and Hospital of Stomatology, Beijing, China.

²Associate Professor, Department of Oral and Maxillofacial Surgery, Peking University School and Hospital of Stomatology, Beijing, China.

³Professor, Department of Oral and Maxillofacial Surgery, Peking University School and Hospital of Stomatology, Beijing, China.

Correspondence to: Dr Xiaofeng Shan, Department of Oral and Maxillofacial Surgery, Peking University School and Hospital of Stomatology, No. 22 South Avenue, Zhongguancun, Haidian District, Beijing 100081 China. Fax: +86 1062173402. Email: kqsxf@263.net

Dr Zhigang Cai, Department of Oral and Maxillofacial Surgery, Peking University School and Hospital of Stomatology, No. 22 South Avenue, Zhongguancun, Haidian District, Beijing 100081 China. Fax: +86 1062173402. Email: c2013xs@163.com

Submitted July 13, 2018; accepted December 15, 2018.

©2019 by Quintessence Publishing Co Inc.

Revascularized bone free flap has been used by most clinicians for jaw reconstruction to improve appearance and recover oral function.^{1,2} Accuracy of jaw reconstruction has improved with the aid of computer-assisted surgery, which, in turn, improves esthetic outcomes as well.³ Computer-assisted surgery, including preoperative virtual planning and computer-assisted intraoperative navigation, was first indicated by Schramm et al for resection of a tumor in the craniomaxillofacial skeleton.⁴ With computer-assisted surgery, individual mandible or maxilla models, cutting guides, and pre-bent plates can be fabricated based on computed tomography (CT) data, which can accurately shape and fix vascularized bone free flaps so that facial contour and oral functions such as speech and deglutition are optimally restored.

Nevertheless, recovery of masticatory function depends on the dental implant technique and prosthetic rehabilitation used. Implant surgeries are much more challenging than conventional dental implant placement in the native bone because both implants and

grafts must be in the optimal position to promote further prosthodontic treatment.⁵ Based on previous studies, the dental rehabilitation rate ranges from 25.7% to 40%, 42.9%, and 90%.⁶⁻⁹ Apart from implant failure, poor patient cooperation, and tumor recurrence, one of the primary reasons for failure of completing a proposed dental reconstruction is an unfavorable intermaxillary relationship between the reconstructed jawbone and opposing jawbone. The ideal of dental implant rehabilitation-guided jaw reconstruction has been proposed to achieve an optimal intermaxillary relationship for rehabilitation of a dental prosthesis on the reconstructed bone. With the computer-assisted technique, placement of bone free flaps can be determined based on location and orientation of an implant during virtual surgical planning to facilitate formation of desirable intermaxillary relationships. The present study was conducted to evaluate the effects of preoperative virtual planning and jaw reconstruction guided by dental implant rehabilitation on the rehabilitation of dental prostheses after jaw reconstruction.

MATERIALS AND METHODS

Ethical Approval

This research was approved by the institutional ethics committee of Peking University School and Hospital of Stomatology (PKUSSIRB-201310110). All patients provided written informed consent to participate in the study.

Patients

From May 2012 to November 2016, patients who were referred for jaw resection and rehabilitation to the Department of Oral and Maxillofacial Surgery, Peking University School and Hospital of Stomatology, Beijing, China, were enrolled in the study.

Inclusion criteria were as follows: (1) segmental resection of the mandible or maxilla was indicated; (2) the patient agreed to undergo mandibular or maxillary reconstruction and further dental implant rehabilitation; (3) a fibular or iliac bone free flap was possible for jaw reconstruction; and (4) the patient could wait 3 to 5 days for creation of a virtual preoperative design. Exclusion criteria were as follows: (1) the patient had an advanced malignant tumor with poor prognosis; (2) the patient was in poor physical condition and could not tolerate surgery; (3) the patient received radiotherapy; (4) the patient did not receive dental implant therapy after jaw reconstruction; and (5) implant placement for < 6 months.

For the choice of bone free flap, the general condition of the patient, the size of the defect area, and the length of the vascular pedicle should be considered.

Patients who received navigation surgery were classified into the navigation group and the others into the non-navigation group according to patients' own choice for a surgical procedure.

Virtual Planning

A therapy group including a maxillofacial surgeon and a prosthodontist conducted preoperative virtual planning. Only the bone defect was considered in virtual planning. Preoperative planning began with acquisition of a CT scan of the patient's maxillofacial and iliac or fibular region with the former acquired in a stable occlusal position (field of view, 250 mm; pitch, 1.0; slice, 1.25 mm; 120 kv 18 mAs). Subsequently, the CT data were saved in DICOM format, and were imported into the ProPlan CMF software (Materialise) to generate three-dimensional (3D) images of the skull and bone graft. The mandible and maxilla were segmented with ProPlan CMF. When determining the tumor border, soft tissue was considered. For the malignant tumor, a virtual segmental mandibulectomy or maxillectomy was performed 15 mm away from the tumor border when the soft tissue was invaded and 10 mm away from the tumor border when it was without soft tissue invasion. For a benign tumor, a virtual segmental mandibulectomy or maxillectomy was performed at least 2 mm away from the tumor border and completely preserved soft tissue when it was without soft tissue invasion. For trauma, a segmental mandibulectomy or maxillectomy was performed along the border and completely preserved soft tissue. Also, the inferior margin of the left mandible was removed when it was less than 5 mm. The 3D fibular or iliac image was superimposed on the defect to form the ideal contour. Virtual implants were placed in the bone free flaps and then adjusted to the optimal location and orientation to achieve the ideal occlusal relationship with the opposing tooth, which is beneficial for fixed implant-supported prosthetic restorations (Fig 1). Next, the bone free flaps were redesigned involving segmentation, length of segments, angulations, and orientation to accommodate implants and ensure adequate space left between the reconstructed bone and the opposing bone. The length of every bone segment and angulations between adjacent bone segments were measured and provided to the surgeon to facilitate intraoperative positioning and placement.

After completing computer simulation, simulation data were imported into the intraoperative navigation system (iPlan 3.0, Brainlab) to guide surgery in the navigation group. On the contrary, data on osteotomy line, bone segmentation, length of segments, and angulation alone were known to the surgeon without any precise guidance in the non-navigation group.

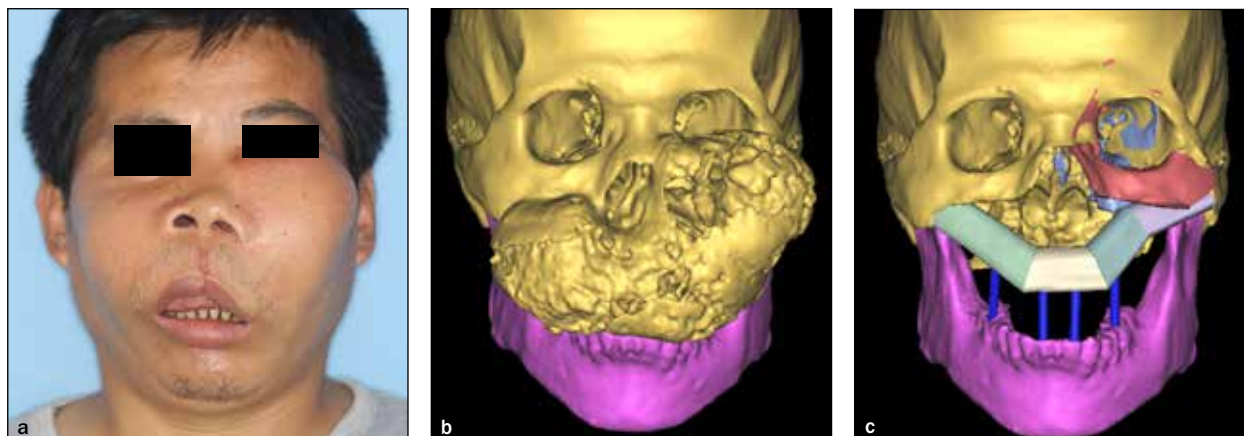
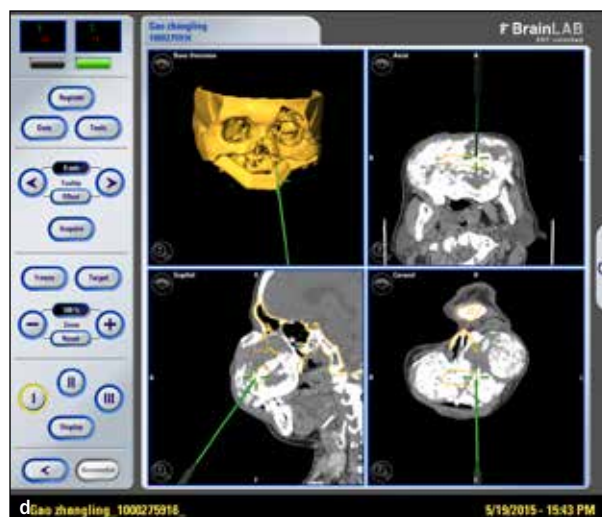
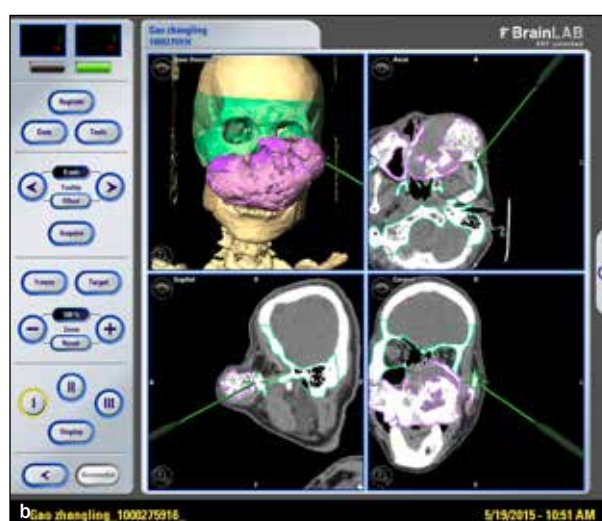
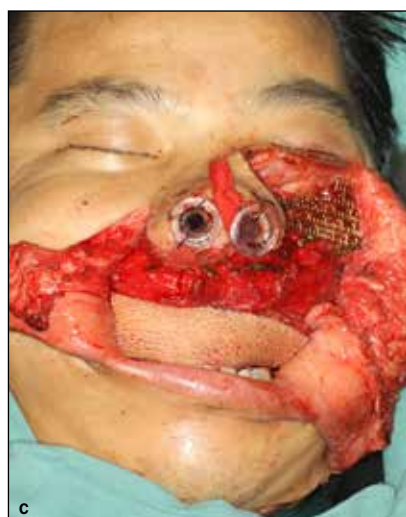
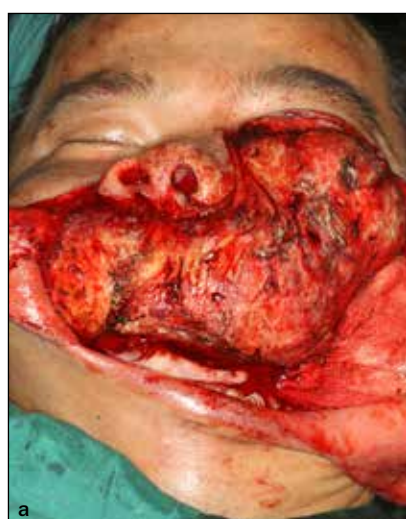
Fig 1 Virtual preoperative design. (a) Preoperative views of facial appearance. (b) CT shows the tumor. (c) The fibular free flap is designed. Subsequently, virtual implants are placed that help in repositioning the fibular free flap.

Fig 2 (a and b) The navigation system was used to check the position of the osteotomy line. (c and d) 3D positions of the bone free flap and titanium mesh were confirmed using the navigation system.



Surgical Technique

A segmental mandibulectomy or maxillectomy was performed using the intraoperative navigation system or manually. Meanwhile, fibular or iliac bone harvesting was performed by another surgical team.

Segmentation and beveling of segments was completed according to the preoperative design created using ProPlan CMF. Subsequently, a bone free flap was inserted into the defect (Fig 2). During navigation surgery, 3D position of the bone free flap was guided and

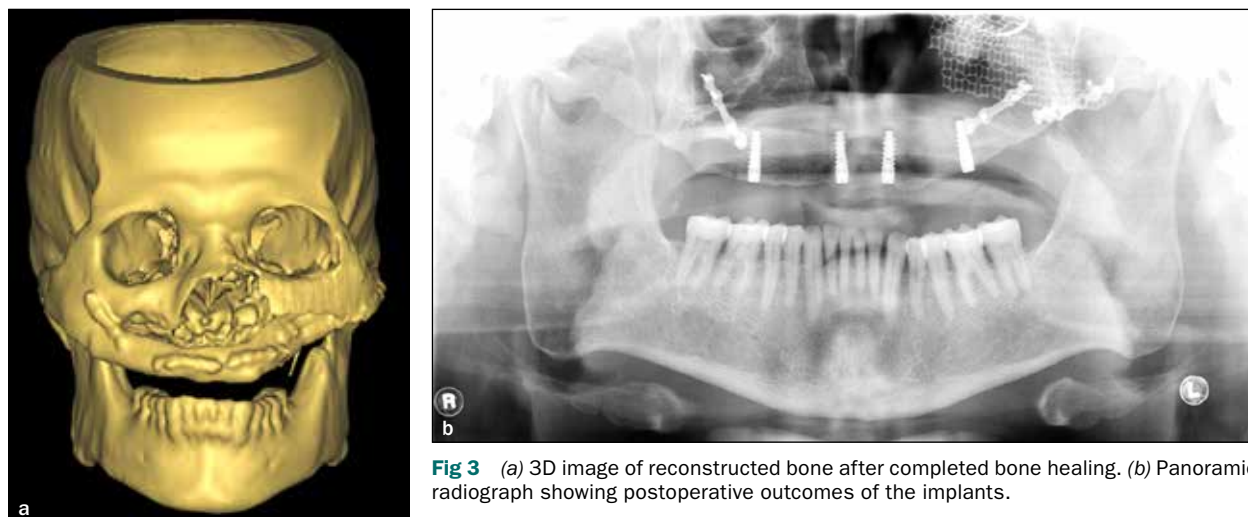


Fig 3 (a) 3D image of reconstructed bone after completed bone healing. (b) Panoramic radiograph showing postoperative outcomes of the implants.

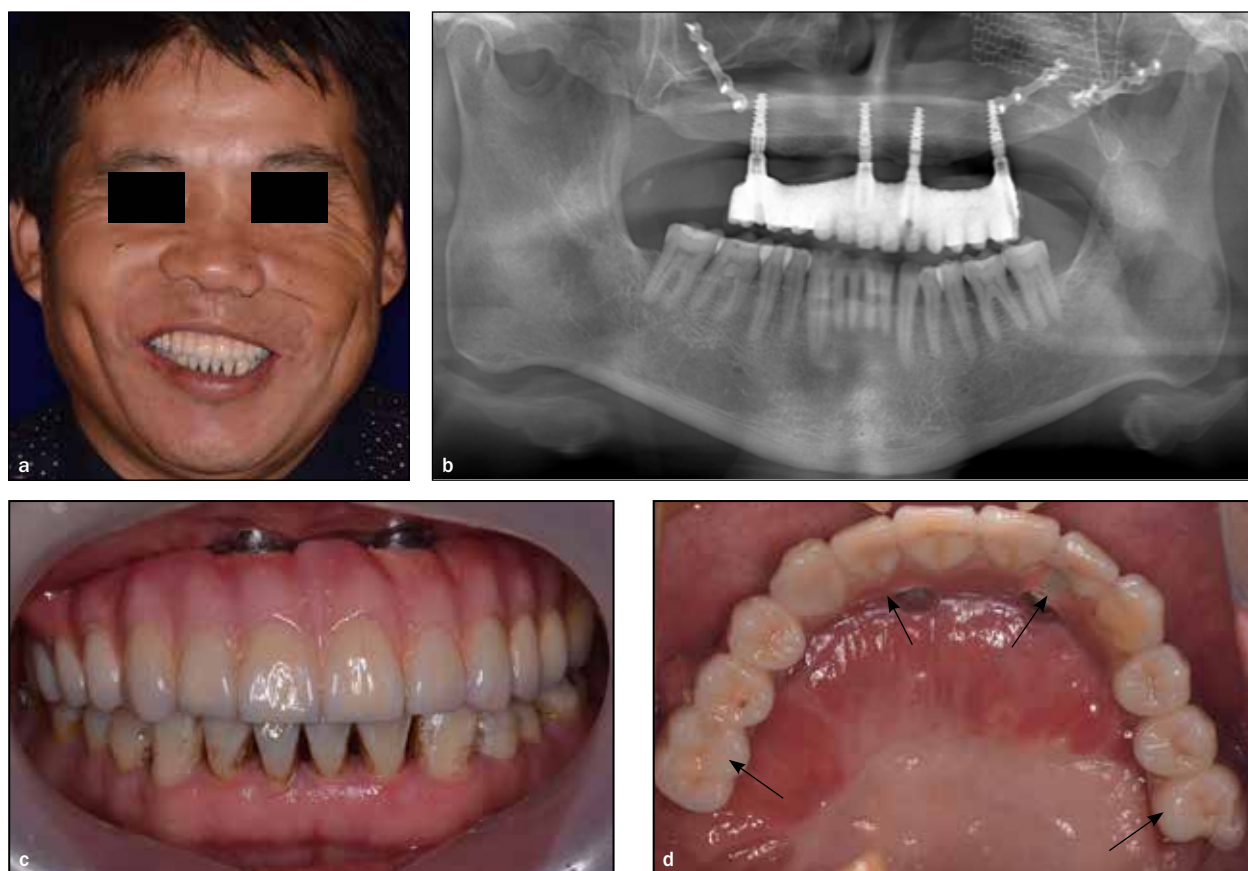

Fig 4 Dental prosthetic rehabilitation with fixed implant-supported prosthesis. (a) View of facial appearance after prosthetic rehabilitation. (b) Panoramic radiograph after placement of prosthesis. (c) Intraoral view showed adequate occlusion with dental prosthesis in place. (d) The four black arrows indicate positions of four implants. All implants are included in the dentition.

checked by the navigation system until all segments corresponded with the ideal preplanned positions. After the bone free flap was moved to the intended position, rigid fixation was placed.

After the reconstructed bone showed complete bone healing, virtual planning was performed by a

maxillofacial surgeon and a prosthodontist to further ensure accurate position of implant placement. A simple guide template of the implant was fabricated and fixed by the remaining teeth of reconstructed jawbone during implant surgery. When no tooth was left, the implant surgery was performed by a maxillofacial

surgeon and a prosthodontist depending on virtual planning data (Fig 3). Dental prosthetic rehabilitation was completed after treatment by a prosthodontist (Fig 4). While considering the prosthesis type, fixed implant-supported prostheses were the first choice. Implant-supported removable dentures were chosen if the requirements for fixed prostheses were not met. Routine radiographic data after implant placement were obtained through panoramic radiographs and CT recorded immediately after implant placement, at the time of prosthetic rehabilitation, and annually thereafter. Implant success was determined as follows: (1) absence of persistent pain; (2) absence of peri-implant infection with suppuration; (3) absence of mobility; (4) absence of continuous peri-implant radiolucency; and (5) peri-implant bone resorption of 1.5 mm in the first year of function and 0.2 mm in the subsequent years.¹⁰

Data Statistics and Analysis

The survival rates of implants, site of reconstruction, type of graft, and type of prosthesis selected were analyzed in all patients. Data entry was performed using the SPSS software (version 20.0, SPSS). Factors that influenced prosthesis selection were investigated using Fisher's exact test. The level of significance was defined as $P < .05$.

RESULTS

In total, 29 eligible patients were included in the study. Patient characteristics are shown in Table 1. Of these, 16 patients belonged to the non-navigation group and 13 belonged to the navigation group.

The main complications that were monitored were donor site complications and recipient site complications including vascular crisis, flap necrosis, infection, etc. No complications were reported by patients, but one patient developed complications of a leg infection after the operation and then healed after therapy of debridement dressing. A total of 101 implants were inserted into the bone flap between 7 and 48 months (mean: 20 months) after reconstruction surgery. The implant success rate was 98.02% during the mean follow-up duration of 28 (range: 8 to 61) months because 2 implants were extracted due to peri-implantitis. All patients received prosthetic rehabilitations. In the navigation group, nine patients received fixed implant-supported prostheses, and the other four received removable dentures. In the non-navigation group, nine patients eventually received fixed implant-supported prostheses, and seven received removable dentures (Table 2).

Of 19 patients with mandibular defects, 11 patients received fixed implant-supported prostheses, and 8 received removable dentures. On the other hand, of 10

Table 1 Summary of Patient Characteristics

	Clinical outcome
Patients	29
Male	14
Female	15
Age	37.5 y (14–61 y)
Diagnosis	
Benign	20
Malignant	7
Trauma	2
Site of reconstruction	
Maxilla	10
Mandible	19
Vascularized bone flap	
Fibula	23
Iliac bone	6
PR SIS	20 mo (7–48 mo)
FDI	28 mo (8–61 mo)
FPR	14 mo (1–51 mo)

y = years; mo = months; PR SIS = period between reconstruction surgery and implant surgery; FDI = follow-up after dental implant placement; FPR = follow-up after prosthetic rehabilitation.

Table 2 Prosthesis Type in Navigation and Non-navigation Groups

	Fixed prosthesis	Removable denture	Total	P value
Navigation group	9 (69.2%)	4 (30.8%)	13 (100%)	.702
Non-navigation group	9 (56.3%)	7 (43.7%)	16 (100%)	
Total	18	11	29	

patients with maxillary defects, 6 received fixed prostheses, whereas 4 received removable dentures. No significant differences were observed in the prosthesis type selected. Use of fixed prostheses was higher among patients with benign tumors compared with those with malignant tumors, but the difference was not significant. Of patients who underwent reconstruction using iliac bone free flaps, 4 had fixed prostheses, whereas of patients who underwent reconstruction using fibular free flaps, 14 had fixed prostheses, but the difference was not significant (Table 3).

Table 3 Prosthesis Type Depending on Clinical Variables

Variables	Fixed prosthesis	Removable denture	P value
Age (y)	34.6 ± 13.6	43.2 ± 13.1	
Site of reconstruction			
Maxilla	7	3	.694
Mandible	11	8	
Bone flap			
Fibula	14	9	1.000
Iliac bone	4	2	
Character of diseases			
Malignant	3	4	.375
Benign	15	7	

DISCUSSION

With development of computer-assisted surgery, one of the greatest challenges in jaw reconstruction is optimizing facial contours more accurately, which is underway. Another major challenge is optimal dental implant and prosthetic rehabilitation on a bone free flap after surgery. Implant survival rates after bone free flap surgery have ranged from 90% to 98%, and 99%, and a similarly high dental implant survival rate was also reported in the present study.^{7,11,12} In the past, during reconstructive surgery, the focus of bone free flap placement has been more on how to recover desirable facial esthetics, and thus, the sagittal relationship between the reconstructed bone and the opposing bone has rarely been taken into account. An inappropriate relationship between the maxilla and mandible is an important factor for accurate fabrication and fit of a dental prosthesis. Poor graft position compromises implant position and angulations, which can eventually impair function and esthetics of a prosthesis and even lead to bone resorption owing to nonaxial overload of implants.^{13,14}

In recent years, efforts in the right direction can help resolve this issue and complete dental rehabilitation. Conventionally, jaw reconstruction is performed by a surgeon who aims to maintain appropriate occlusal relationships after assessing patients' dentition and occlusion based on their extensive clinical experience.¹⁵ In addition, with application of computer-assisted technology, surgical templates are obtained by virtual implant planning to guide implant location on the reconstructed bone, which can further facilitate prosthetic rehabilitation. However, this method still requires an appropriate relationship between the reconstructed and the opposing bone along with adequate interarch distance.¹⁶

Based on aforementioned factors, preoperative virtual surgical planning for jaw reconstruction is considered a favorable option. A web-based conference involving the surgical and prosthodontic teams is held before surgery, and detailed surgical guidance is prepared. Compared with conventional reconstructions, although virtual planning includes more complex flap designs, it facilitates high rates of successful dental rehabilitation along with reduced operative times and increased accuracy of reconstruction.¹⁷⁻¹⁹ The present study adopted virtual surgical planning for jaw reconstruction. With the help from the surgical and prosthodontic teams, virtual implants were used to guide placement of bone free flaps. Eventually, an implant success rate of 98.06% and a dental rehabilitation rate of 100% were achieved.

Dental implant rehabilitation on the reconstructed bone can be either fixed or removable prostheses. Removable dentures can partially support facial soft tissues, be easy to clean, and partly resolve speech and esthetic issues. However, these dentures have poor retention and stability and are uncomfortable. Fixed prostheses have higher masticatory efficiency and better retention.²⁰ A previous systematic review and meta-analysis estimated implant loss and corresponding 3- and 5-year survival rates for fixed and removable restorations; implant loss rates for fixed restorations were significantly lower compared with removable restorations.²¹ Moreover, assessment of patient satisfaction and oral health-related quality of life in patients treated with implant-supported removable dentures and complete implant fixed prostheses revealed that removable dentures had significantly lower overall satisfaction as well as lower satisfaction in terms of masticatory efficiency and esthetics.²² Accordingly, fixed implant-supported prosthetic restorations are considered the best solution for dental rehabilitation.²³ Hence, fixed implant-supported prostheses were the authors' first choice for dental rehabilitation for the present study.

However, accurate placement and maintenance of fixed implant-supported prosthetic restorations can be challenging. This is because only a small range of axial inclination of an implant is compatible with maintaining biomechanical force transmission in a favorable orientation for fixed implant-supported prostheses.²⁴ Unfavorable implant axial inclination can lead to increased maximum equivalent stress in the cortical bone, which further results in implant overloading and endangers longevity of prosthetic restorations.²⁵ Only an optimal positional relationship between a dental implant and a bone free flap can meet the ideal requirements of fixed prostheses. Based on previous studies, the success rate of fixed implant-supported prosthetic restorations ranges from 22% to 57.1%, and 100%.^{24,26,27} Although some

research reported high success rates of fixed prostheses, the success rate is low in most studies. In the present study, the total rate of fixed prostheses was 62.1%, and this rate was as high as 69.2% in the navigation group. During virtual surgical planning, at the beginning, with help from the prosthodontist, axial inclination of the dental implant was designed in a way so that it conformed to requirements of both bone graft positioning and fixed prosthesis rehabilitation.

Virtual surgical planning can offer satisfactory postoperative effects in theory, but the ability to transfer a proposed plan into actual results is vital. Shan et al achieved satisfactory repeatability between virtual plans and actual results ($91.9\% \pm 5.4\%$ within 3 mm) in surgical navigation-assisted mandibular reconstruction, demonstrating that surgical navigation combined with virtual planning was feasible and precise.²⁸ After virtual planning, is surgical navigation necessary to achieve good results? Yu et al²⁹ reported the difference between use of navigation combined with virtual planning and virtual planning alone. The average gonion shift (distance between reconstructed and ideal gonion positions) was significantly greater in the single virtual plan group (12.5 ± 3.8 mm) compared with the navigation combined with virtual plan group (7.3 ± 2.5 mm); however, no significant differences were noted in the average condylar shift (distance between reconstructed and ideal condylar positions) between both groups (10.3 ± 3.9 and 9.3 ± 2.6 mm, respectively). The study concluded that differences between both groups were not significant. From the results of the present study, the rate of fixed implant-supported prostheses was 69.2% in the navigation group and 56.3% in the non-navigation group, which also indicated no significant differences in the rate of fixed implant-supported prostheses with or without the use of navigation after virtual planning.

Moreover, all potential impact factors of prosthesis selection that were evaluated showed no significant correlation with type of prosthesis. Larger samples and randomized studies are needed to further analyze factors that influence selection of prosthesis type.

CONCLUSIONS

Preoperative virtual planning and dental implant rehabilitation-guided jaw reconstruction through preoperative designing can provide a good opportunity to achieve high rates of implant success and dental rehabilitation. This method can also benefit fixed implant-supported prosthetic restorations. Moreover, use of navigation after virtual planning has no effect on the type of prosthetic reconstruction.

ACKNOWLEDGMENTS

This work was supported by the National Key Research and Development Program of China [grant number 2016YFC1102902] and the Beijing Municipal Development Foundation of China [grant numbers Z171100001017129, Z161100000516016]. The authors are also grateful to the prosthodontists Dr Yanjun Ge, Dr Zhaoqiang Meng, and Dr Dong Han for the prosthetic rehabilitation. The authors reported no conflicts of interest related to this study.

REFERENCES

- Hidalgo DA. Fibula free flap: A new method of mandible reconstruction. *Plast Reconstr Surg* 1989;84:71–79.
- Cordeiro PG, Disa JJ, Hidalgo DA, Hu QY. Reconstruction of the mandible with osseous free flaps: A 10-year experience with 150 consecutive patients. *Plast Reconstr Surg* 1999;104:1314–1320.
- Roser SM, Ramachandra S, Blair H, et al. The accuracy of virtual surgical planning in free fibula mandibular reconstruction: Comparison of planned and final results. *J Oral Maxillofac Surg* 2010;68:2824–2832.
- Schramm A, Gellrich NC, Gutwald R, et al. Indications for computer-assisted treatment of cranio-maxillofacial tumors. *Comput Aided Surg* 2000;5:343–352.
- Zheng GS, Su YX, Liao GQ, et al. Mandible reconstruction assisted by preoperative virtual surgical simulation. *Oral Surg Oral Med Oral Pathol Oral Radiol* 2012;113:604–611.
- Hundepool AC, Dumans AG, Hofer SO, et al. Rehabilitation after mandibular reconstruction with fibula free-flap: Clinical outcome and quality of life assessment. *Int J Oral Maxillofac Surg* 2008;37:1009–1013.
- Adell R, Svensson B, Bågenholm T. Dental rehabilitation in 101 primarily reconstructed jaws after segmental resections—possibilities and problems. An 18-year study. *J Craniomaxillofac Surg* 2008;36:395–402.
- Smolka K, Kraehenbuehl M, Eggensperger N, et al. Fibula free flap reconstruction of the mandible in cancer patients: Evaluation of a combined surgical and prosthodontic treatment concept. *Oral Oncol* 2008;44:571–581.
- Rohner D, Jaquière C, Kunz C, Bucher P, Maas H, Hammer B. Maxillofacial reconstruction with prefabricated osseous free flaps: A 3-year experience with 24 patients. *Plast Reconstr Surg* 2003;112:748–757.
- Albrektsson T, Zarb G, Worthington P, Eriksson AR. The long-term efficacy of currently used dental implants: A review and proposed criteria of success. *Int J Oral Maxillofac Implants* 1986;1:11–25.
- Foster RD, Anthony JP, Sharma A, Pogrel MA. Vascularized bone flaps versus nonvascularized bone grafts for mandibular reconstruction: An outcome analysis of primary bony union and endosseous implant success. *Head Neck* 1999;21:66–71.
- Sozzi D, Novelli G, Silva R, Connelly ST, Tartaglia GM. Implant rehabilitation in fibula-free flap reconstruction: A retrospective study of cases at 1–18 years following surgery. *J Craniomaxillofac Surg* 2017;45:1655–1661.
- Zlotolow IM, Huryn JM, Piro JD, Lenchewski E, Hidalgo DA. Osseointegrated implants and functional prosthetic rehabilitation in microvascular fibula free flap reconstructed mandibles. *Am J Surg* 1992;164:677–681.
- Roumanas ED, Markowitz BL, Lorant JA, Calcaterra TC, Jones NF, Beumer J 3rd. Reconstructed mandibular defects: Fibula free flaps and osseointegrated implants. *Plast Reconstr Surg* 1997;99:356–365.
- Bak M, Jacobson AS, Buchbinder D, Urken ML. Contemporary reconstruction of the mandible. *Oral Oncol* 2010;46:71–76.
- Meloni SM, Tallarico M, De Riu G, et al. Guided implant surgery after free-flap reconstruction: Four-year results from a prospective clinical trial. *J Craniomaxillofac Surg* 2015;43:1348–1355.

17. Broer PN, Tanna N, Franco PB, et al. Ten-year evolution utilizing computer-assisted reconstruction for giant ameloblastoma. *J Reconstr Microsurg* 2013;29:173–180.
18. Avraham T, Franco P, Brecht LE, et al. Functional outcomes of virtually planned free fibula flap reconstruction of the mandible. *Plast Reconstr Surg* 2014;134:628e–634e.
19. Rodby KA, Turin S, Jacobs RJ, et al. Advances in oncologic head and neck reconstruction: Systematic review and future considerations of virtual surgical planning and computer aided design/computer aided modeling. *J Plast Reconstr Aesthet Surg* 2014;67:1171–1185.
20. Zitzmann NU, Marinello CP. Treatment outcomes of fixed or removable implant-supported prostheses in the edentulous maxilla. Part I: Patients' assessments. *J Prosthet Dent* 2000;83:424–433.
21. Kern JS, Kern T, Wolfart S, Heussen N. A systematic review and meta-analysis of removable and fixed implant-supported prostheses in edentulous jaws: Post-loading implant loss. *Clin Oral Implants Res* 2016;27:174–195.
22. Brennan M, Houston F, O'Sullivan M, O'Connell B. Patient satisfaction and oral health-related quality of life outcomes of implant overdentures and fixed complete dentures. *Int J Oral Maxillofac Implants* 2010;25:791–800.
23. Chiapasco M, Biglioli F, Autelitano L, Romeo E, Brusati R. Clinical outcome of dental implants placed in fibula-free flaps used for the reconstruction of maxillo-mandibular defects following ablation for tumors or osteoradionecrosis. *Clin Oral Implants Res* 2006;17:220–228.
24. Raoul G, Ruhin B, Briki S, et al. Microsurgical reconstruction of the jaw with fibular grafts and implants. *J Craniofac Surg* 2009;20:2105–2117.
25. Alvarez-Arenal A, Gonzalez-Gonzalez I, deLlanos-Lanchares H, Brizuela-Velasco A, Martin-Fernandez E, Ellacuria-Echebarria J. Influence of implant positions and occlusal forces on peri-implant bone stress in mandibular two-implant overdentures: A 3-dimensional finite element analysis. *J Oral Implantol* 2017;43:419–428.
26. He Y, Zhang ZY, Zhu HG, Wu YQ, Fu HH. Double-barrel fibula vascularized free flap with dental rehabilitation for mandibular reconstruction. *J Oral Maxillofac Surg* 2011;69:2663–2669.
27. Meloni SM, Tallarico M, De Riu G, et al. Guided implant surgery after free-flap reconstruction: Four-year results from a prospective clinical trial. *J Craniomaxillofac Surg* 2015;43:1348–1355.
28. Shan XF, Chen HM, Liang J, et al. Surgical navigation-assisted mandibular reconstruction with fibula flaps. *Int J Oral Maxillofac Surg* 2016;45:448–453.
29. Yu Y, Zhang WB, Liu XJ, Guo CB, Yu GY, Peng X. Three-dimensional accuracy of virtual planning and surgical navigation for mandibular reconstruction with free fibula flap. *J Oral Maxillofac Surg* 2016;74:1503.e1–1503.e10.