

The accuracy of cone-beam computed tomography in assessing maxillary molar furcation involvement

Jing Qiao¹, Shiyong Wang¹, Jinyu Duan¹, Yong Zhang¹, Yun Qiu¹, Changzhou Sun¹ and Denggao Liu²

¹Department of Periodontology, Outpatient Center, School and Hospital of Stomatology, Peking University, Beijing, China;

²Department of Radiology, School and Hospital of Stomatology, Peking University, Beijing, China

Qiao J, Wang S, Duan J, Zhang Y, Qiu Y, Sun C, Liu D. The accuracy of cone-beam computed tomography in assessing maxillary molar furcation involvement. *J Clin Periodontol* 2014; 41: 269–274. doi: 10.1111/jcpe.12150.

Abstract

Aim: The aim of this study was to investigate the accuracy of cone-beam computed tomography (CBCT) in assessing maxillary molar furcation involvement (FI).

Materials and Methods: Fifteen patients with generalized chronic periodontitis after initial therapy were recruited. CBCT was performed in maxillary molars with probing pocket depths of ≥ 6 mm and advanced FI, and CBCT images were analysed. Furcation surgery was performed in 20 maxillary molars. Lastly, intra-surgical FI assessments were compared with CBCT-based data.

Results: Intra-surgical findings confirmed 82.4% of the CBCT data, with a weighted kappa of 0.917. The agreement between both assessments was the highest in buccal furcation entrances, followed by distopalatal and mesiopalatal furcation entrances. Of the four parameters tested of detailed root anatomy and furcation morphology, the mean length of the root trunk and the width of the furcation entrance revealed by CBCT were consistent with their respective intra-surgical values ($p > 0.05$). Horizontal bone loss and vertical bone loss were underestimated by CBCT relative to their respective intra-surgical classifications ($p \leq 0.05$).

Conclusions: Cone-beam computed tomography images demonstrate a high accuracy in assessing the loss of periodontal tissue of the FI and root morphologies in maxillary molars.

Key words: cone-beam computed tomography; diagnostic tools; furcation involvement; periodontal; treatment planning

Accepted for publication 23 July 2013

Periodontists commonly encounter the difficulty of accurately assessing and treating furcations affected by periodontal disease. Molars are typically the teeth most highly damaged

by this disease, and concomitant furcation involvement (FI) significantly increases the likelihood of requiring complete resection. The precise diagnosis of FI must be obtained before a prognosis and treatment strategy can be established.

Diagnosis is generally based on probing pocket depth, probing attachment level, probing of the furcation entrance and periapical radiographs (Pihlstrom 2001). Accurate clinical analysis of FI is, however, not feasible in many instances due to

limited physical access to the depths of the furcation, morphological variations and measurement errors. The chief limitation of current conventional intra-oral imaging for FI is conspicuity, which is largely the result of the representation of a three-dimensional (3D) structure depicted by a two-dimensional (2D) image. Thus, additional diagnostic modalities for FI are necessary (Vandenbergh et al. 2011).

Use of cone-beam computed tomography (CBCT), an advanced

Conflict of interest and source of funding statement

The authors declare that there are no conflicts of interest in this study. No external funding, apart from the support of the authors' institution, was available for this study.

application of computed tomography (CT), has increased rapidly in the dental field since its inception in 2004. CBCT provides the ability to collect data at higher resolutions and generate 3D data at both lower cost and lower absorbed doses than conventional CT (Ito et al. 2001). Moreover, the accuracy of CBCT to diagnose molar FI has been verified in vitro and in patients, confirmed against intra-surgical findings and a variety of periodontal defects have been identified and quantified using this application (Pinsky et al. 2006, Walter et al. 2009, 2010, Zhong et al. 2010). Three-dimensional CBCT images have also revealed the surrounding bony support of each maxillary molar root, fusion and root proximity; therefore, these images may be a reliable basis for making treatment decisions (Walter et al. 2009).

Overall, CBCT may be poised to succeed current intra-oral imaging methods for the assessment of periodontal architecture; however, more clinical studies are needed to support this conclusion. The aim of this study, therefore, was to investigate the accuracy of dental CBCT in assessing FI in maxillary molars. In addition to determining the degree of FI, this study provides more evidence of the accuracy of CBCT in the 3D measurement of FI. The data generated by CBCT were compared with intra-surgical assessment of FI.

Materials and Methods

Study population

The study group was comprised of 15 patients (9 women and 6 men) with an average age of 43.5 years and a diagnosis of generalized chronic periodontitis. Initial therapy, including oral hygiene instruction, scaling and root planing with ultrasonic devices and hand instruments and occlusal adjustment, was completed, and re-evaluations were performed after 3 or 6 months. Periodontal surgery was considered for patients with at least one maxillary molar with probing pocket depth (PPD) of ≥ 6 mm and advanced FI, defined as horizontal inter-radicular loss of periodontal tissues of degree 2 or 3 (Hamp et al. 1975). Patients with any one of the following condi-

tions were excluded from the study: patients with furcation caries, metal crowns in the CBCT irradiation area or silver amalgam fillings near the alveolar crest and women who were pregnant or lactating. Overall, 11 first maxillary molars and 9 s maxillary molars with a combined total of 51 furcation entrances were included (Table 1). All patients were informed of the purpose of this study and signed an informed consent form. The protocol and consent form were approved by the Ethics Committee of Peking University Health Science Center, Beijing, China.

Pre-surgical clinical measurements

The following clinical evaluations of the included maxillary molars were performed by two trained periodontists whose measurements were calibrated before the start of the study. Inter-observer agreement produced a Cohen's kappa (κ) of 0.729. The two periodontists who recorded pre-surgical parameters were blinded to CBCT data.

Probing pocket depth was measured to the nearest millimetre at six sites (mesiobuccal, buccal, distobuccal, distopalatal, palatal and mesio-palatal) of the selected maxillary molars using a periodontal probe graded in millimetres (PCPUNC-15; HU-Friedy, Chicago, IL, USA).

FI was measured at three sites (buccal, mesio-palatal and distopalatal) of the selected maxillary molars using a curved scaled Nabers probe marked at 3 mm intervals (PQ2N; HU-Friedy). The degree of FI was graded according to Hamp et al.'s (1975) classification system:

- Degree 0: no horizontal loss of periodontal tissue support, i.e. no radiolucency in the furcation area.
- Degree I: horizontal loss of periodontal tissue support up to 3 mm.

- Degree II: horizontal loss of support exceeding 3 mm, but no "through and through" destruction.
- Degree III: horizontal "through and through" destruction of the periodontal tissue in the furcation.

Measurements of dental CBCT

Prior to surgery, CBCT was performed in the posterior maxillary area using the high-resolution imaging system 3D Accuitomo 60, XYZ Slice View Tomograph (J. Morita, Kyoto, Japan). Cylindrical volumes of $4 \times 4 - 6 \times 6$ cm, settings in the range 74–90 kV and 5–8 mA and voxel size of $0.125 \times 0.125 \times 0.125$ mm were used depending on the region of interest. The slice thickness was set at 0.5 mm, and the pitch was set at 0.125 mm. After post-processing, a reconstruction algorithm generated super-high-resolution 3D images displayed on the computer monitor. The images were viewed by two trained radiographers on a 19" Viewsonic VA703B monitor (Viewsonic, Walnut, CA, USA) set at a screen resolution of 1280×1024 pixels. No time restriction was placed on the observers, and images were viewed at 1-week intervals. The two radiographers were blinded to the pre-surgical and intra-surgical clinical recordings. When evaluating the images, the room lights were turned off. Measurements were made to the nearest 0.01 mm using the i-Dixel-3DX software (J. Morita) with a linear measurement tool and a digital magnification lens. The three axes (X, Y and Z) of the CBCT images were sequentially analysed (Fig. 1). Inter-observer agreement produced a Cohen's kappa of 0.718. Each slice was analysed for the separate measures.

Table 1. Pre-surgical, CBCT and intra-surgical furcation involvement (FI) distribution

Degree of FI	0	I	II	III	Total
Pre-surgical distribution	7	5	30	9	51
Percentage (%)	13.7	9.8	58.9	17.6	100
CBCT distribution	4	10	28	9	51
Percentage (%)	7.8	19.6	55.0	17.6	100
Intra-surgical distribution	2	11	26	12	51
Percentage (%)	3.9	21.6	51.0	23.5	100

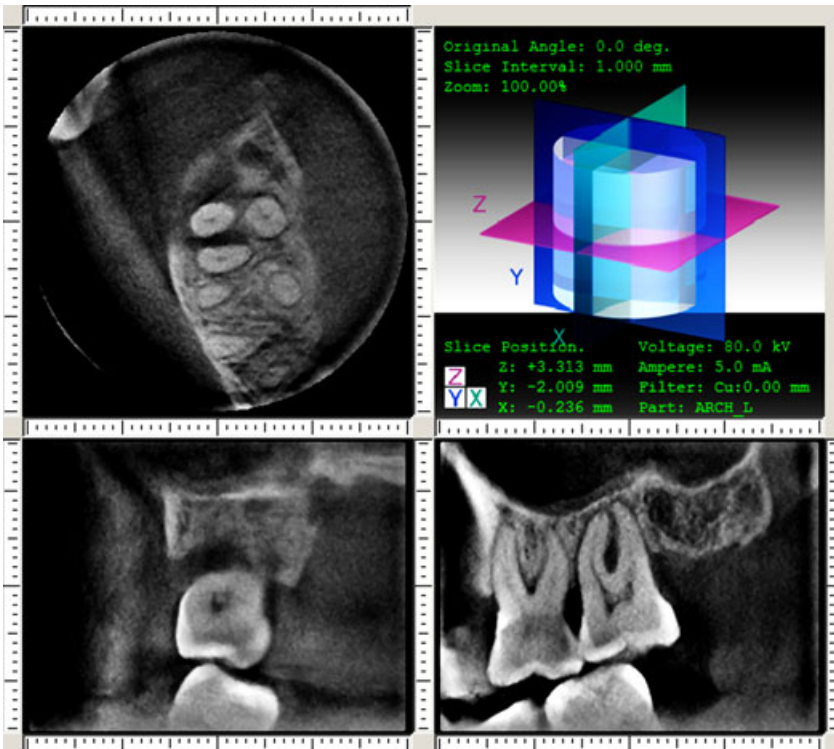


Fig. 1. CBCT with horizontal, sagittal and transverse sections of the first and the second left maxillary molars (subject No. 5).

Furcation involvement was calculated in the horizontal plane by measuring, to the nearest millimetre, the distance between the outer root surface and the inter-radicular bone (bone loss in the horizontal direction – ‘BL-H’). The degree of FI was graded according to Hamp et al.’s (1975) classification system. Vertical bone loss (BL-V) in the furcation was measured in the X section (Fig. 1). Degree of BL-V was decided by measuring the distance from the furcation entrance to the base of the defect in the vertical direction. The length of the root trunk (RT) was measured in the X section (buccal RT) and Y section (mesiopalatal and distopalatal RTs) and the distance from the cemento-enamel junction (CEJ) to the furcation entrance was measured. The width of the furcation entrance (FW) was measured in the Y section (buccal and distopalatal furcations) and Z section (mesiopalatal furcation). FW for the buccal furcation was a measure of the greatest mesial–distal distance in the furcation, and FW for the mesiopalatal and distopalatal furcations was a measure of the greatest buccal–palatal distance in the furcation.

Intra-surgical clinical measurements

The patients were administered local anaesthesia, flaps were reflected, defects were debrided and all direct surgical measurements were made. Hard tissue measurements rounded up to the nearest 0.5 mm were taken for each defect using a curved scaled Nabers probe (PQ2N; HU-Friedy), marked at 3 mm intervals, and a manual 15 mm periodontal probe (PCPUNC-15; HU-Friedy). Defects were then evaluated by two trained periodontists blinded to the previously obtained pre-surgical clinical recordings and CBCT data. Inter-observer agreement produced a Cohen’s kappa of 0.703.

FI was classified at three sites (buccal, mesiopalatal and distopalatal) of the suspected maxillary molars according to measurements taken with a curved scaled Nabers probe (PQ2N; HU-Friedy), marked at 3 mm intervals (Hamp et al. 1975). Degree of BL-V in the furcation was decided by measuring the distance from the furcation entrance to the base of the defect in the vertical direction. RT was a measure of the distance from the CEJ to the furcation entrance. FW for the buccal furcation was a measure of the

greatest mesial–distal distance in the furcation, and FW for the mesial and distal furcations was a measure of the greatest buccal–palatal distance in the furcation. A schematic diagram of intra-surgical measurements of the buccal furcation was shown in Fig. 2.

Wounds were sutured using size 5-0 monofilament polypropylene sutures (Prolene, Ethicon; Johnson and Johnson, Somerville, NJ, USA), and patients were advised to rinse twice a day with 0.12% chlorhexidine. Sutures were removed 2 weeks after surgery. The intra-surgical clinical findings of the left maxillary molars of subject No. 5 were shown in Fig. 3.

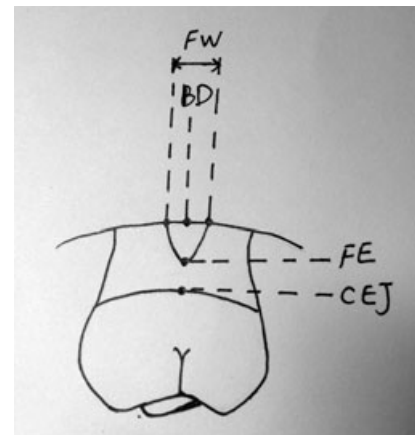


Fig. 2. A schematic diagram of intra-surgical measurements of the buccal furcation. FE, furcation entrance; BD, the base of the defect; CEJ, the cemento-enamel junction; BL-V, the distance from the furcation entrance to the base of the defect in the vertical direction. RT (the length of the root trunk), the distance from the CEJ to FE. FW (the width of the furcation entrance), for the buccal furcation was the greatest mesial–distal distance in the furcation.

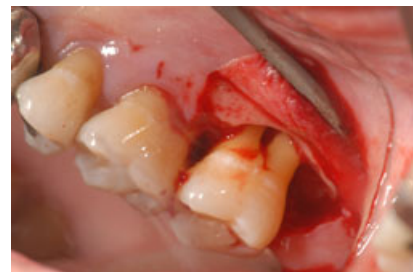


Fig. 3. Pre-surgical measurements of the second left maxillary molar of subject 5: probing pocket depths (mb/b/db/mp/p/dp) 4/7/5/3/3/5 mm, FI (b/mp/dp) II/0/0.

Statistical analysis

A power analysis determined that a sample size of 30 defects would be sufficient to detect a difference of <5% between surgical and radiographic measurements. A frequency distribution was used to determine the inter- and intra-examiner agreement for direct surgical measurements. The rate of agreement between FI classifications was analysed using Cohen's kappa with 95% confidence intervals. According to the six-level nomenclature (Landis & Koch 1977), kappa values between 0.81 and 0.92 are considered to be an almost perfect agreement. A paired *t*-test was used to determine whether a statistically significant difference existed between CBCT compared with direct surgical measurements. A *p* value of ≤ 0.05 was used for all statistical analyses.

Results

Intra-surgical FI distribution

FI measurements recorded prior to and during surgery and CBCT findings are presented in Table 1. Intra-surgical findings revealed an FI of degree I in 11 entrances, degree III in 12 entrances and degree II in 26 entrances (51.0%, majority). Pre-surgical findings showed an FI of degree II in 30 entrances (58.9%, majority). CBCT findings revealed an FI of degree II in 28 entrances (55%, majority), degree I in 10 entrances and degree III in 9 entrances. Furcation surgery included an open flap debridement of 12 molars, guided tissue regeneration of six molars and root amputation of two molars.

Comparison of FI classification in pre-surgical conventional, CBCT and intra-surgical assessment

Overall, intra-surgical findings confirmed 82.4% of the CBCT data, with a weighted kappa of 0.917 (95% CI: 0.681–1.0), indicating a high degree of accuracy. However, only 21.6% of the pre-surgical conventional data were completely consistent with the intra-surgical FI assessments. CBCT data underestimated 11.8% of maxillary furcations (CBCT less than intra-surgical value)

and overestimated 5.9% (CBCT more than intra-surgical value), relative to the intra-surgical data, whereas pre-surgical conventional assessment underestimated 4.1% and overestimated 33.3% (Table 2).

A separate analysis of the three furcation entrances is shown in Table 3. CBCT and intra-surgical classifications were in strongest agreement at the buccal ($\kappa = 0.96$) and distopalatal entrances ($\kappa = 0.94$). Pre-surgical and intra-surgical classifications were in the strongest agreement at the buccal ($\kappa = 0.40$) and mesiopalatal entrances ($\kappa = 0.34$).

Comparison of FI measurements in CBCT and intra-surgical assessment

Each of the parameters evaluated during surgery could also be measured by CBCT. Intra-surgical and CBCT measurements of these parameters were analysed with a paired *t*-test, and the results are shown in Table 4. No significant difference was noted between intra-surgical and CBCT measurements for RT or FW ($p > 0.05$). However, there was a significant difference between intra-

surgical and CBCT measurements for BL-H and BL-V ($p \leq 0.05$), although mean differences were no more than 0.5 mm (0.37 and 0.36 mm respectively).

Discussion

In this investigation, CBCT-generated data of FI in maxillary molars were analysed in comparison with intra-surgical assessments, the current "gold standard" for diagnosis of FI. This study has demonstrated that CBCT assessment of maxillary molar FI is in strong agreement with that of intra-surgical measurements, thus CBCT appears to offer a significant advantage over conventional clinical assessments. Furthermore, CBCT-generated data added a substantial amount of information about the form of the furcation and the severity of the lesions that cannot currently be obtained from conventional clinical assessments.

In this study, the overall agreement of FI classification between CBCT data and intra-surgical findings was strong, with a Cohen's weighted kappa of 0.917. These findings were consistent with those of

Table 2. Agreement between pre-surgical, CBCT and intra-surgical FI findings

Findings	Intra-surgical	Overestimation	Underestimation
CBCT assessment (%)	82.4	5.9	11.7
Pre-surgical assessment (%)	21.6	33.3	45.1

CBCT, cone-beam computed tomography; FI, furcation involvement.

Table 3. Agreement between pre-surgical, CBCT and intra-surgical FI classification in different locations

Furcation location	All sites	Buccal	Mesiopalatal	Distopalatal
κ (CBCT)	0.917	0.96	0.88	0.94
Percentage of complete agreement (%)	82.4	89.4	80.0	87.5
κ (pre-surgical)	0.375	0.40	0.34	0.24
Percentage of complete agreement	21.6	31.6	18.8	12.5

CBCT, cone-beam computed tomography; FI, furcation involvement.

Table 4. Difference between cone-beam computed tomography (CBCT) measurements and intra-surgical measurements

	CBCT (mean \pm SD) (mm)	Intra-surgical (mean \pm SD) (mm)	<i>p</i>
BL-H (horizontal bone loss)	2.11 \pm 1.08	2.48 \pm 1.13	0.01*
BL-V (vertical bone loss)	4.05 \pm 1.73	4.41 \pm 1.62	0.03*
RT (length of root trunk)	3.56 \pm 1.17	3.54 \pm 1.04	0.75
FW (width of furcation entrance)	1.39 \pm 0.75	1.41 \pm 0.88	0.13

* $p \leq 0.05$.

Walter et al. (2010). According to Walter et al., 84% of their CBCT data were confirmed by intra-surgical findings, with a weighted kappa of 0.926. A separate analysis of the three furcation locations showed the greatest degree of agreement between CBCT and intra-surgical measurements for the buccal ($\kappa = 0.96$) and distal ($\kappa = 0.94$) entrances, whereas agreement for the mesial measurements amounted to a weighted kappa of 0.88. In Walter et al.'s study, the largest discrepancies existed for mesial furcation entrances ($\kappa = 0.89$), whereas the agreement in buccal and distal entrances was $\kappa = 0.94$ and $\kappa = 0.95$ respectively.

Detailed root anatomy and furcation morphology were also estimated in this study. The results further demonstrate that CBCT provides substantial additional information about the root morphology and the residual attachment of maxillary molars. In addition to the degree of furcation, this study verified the accuracy of CBCT on the 3D measurements of FI bone level *in vivo*. These CBCT-derived data can help in understanding the severity and morphology of bony defects of the furcation lesion and provide more evidence for periodontal diagnosis and treatment planning. Recently, Feijo et al. evaluated the accuracy of CBCT in the measurement of horizontal periodontal bone defects. They measured periodontal bone defects of eight maxillary molars during surgery and compared the results with data taken from CBCT images. The results showed that CBCT accurately reproduced the clinical measurement of horizontal periodontal bone defects (Feijo et al. 2012). Zhong et al. evaluated the accuracy of measurement of degree II furcation involvements in molars of dry mandibles by CBCT. They measured the vertical defect dimension, horizontal defect dimension and furcation entrance dimension of each FI by probing and CBCT and found that CBCT could provide precise and detailed 3D images of degree II furcation involvements *in vitro* (Zhong et al. 2010).

Of the four parameters assessed in this study, the intra-surgical findings of two were confirmed in the CBCT-based data. RT revealed by CBCT was 3.56 ± 1.17 mm, which was con-

sistent with the intra-surgical value of 3.54 ± 1.04 mm ($p > 0.05$). The difference between FW based on CBCT data and intra-surgical assessment was not statistically significant ($p > 0.05$), 1.39 ± 0.75 mm and 1.41 ± 0.88 mm respectively. The other two parameters, BL-H and BL-V, were underestimated by CBCT relative to their respective intra-surgical values ($p \leq 0.05$). However, the difference was only $0.27 \sim 0.36$ mm, lower than the 0.5 mm minimum accuracy of periodontal probing. Therefore, the error between CBCT-based data and intra-surgical assessment of maxillary molar FI could be accepted in periodontal clinical application. In other words, CBCT-based data accurately reflects the true state of maxillary molar FI. Several studies evaluated the accuracy of CT in the FI of dry maxilla and mandible (Fuhrmann et al. 1995, Mengel et al. 2005, Pinsky et al. 2006). The results showed that the error between CT and actual measurements varied from 0.16 to 0.41 mm, consistent with the findings in this study.

One explanation of the error that exists between CBCT and direct clinical measurements is the different accuracy of both measurements. In this study, probing measurements were only able to be made to the nearest 0.5 mm, whereas CBCT measurements were able to be made to the nearest 0.01 mm. Another explanation may be the location of the furcation entrance. Santana et al. (2004) observed 100 extracted permanent human mandibular molars and found that clinical measurements of horizontal probing depth that used the external surfaces of roots as reference points overestimated the true anatomical component of FI in mandibular molars.

Successful treatment of molar furcation defects is a difficulty commonly faced by periodontists. Available knowledge of the relevant anatomic morphologies associated with these defects should improve their diagnosis and therapeutic management. Vandenberghe et al. (2007) investigated periodontal bone architecture using 2D CCD and 3D full-volume CBCT-based imaging modalities, concluding that CBCT images demonstrated more potential than CCD for describing periodontal bone defect morphologies. Similar

results were described in a study using a dry skull with artificial defects and full-volume CBCT, demonstrating the accuracy of CBCT compared with direct measurement of inter-proximal areas with a periodontal probe (Misch et al. 2006). Furthermore, CBCT was shown to be superior to conventional radiography in assessing buccal and lingual defects.

The use of CBCT over conventional CT for periodontal applications is evident in its superior image quality. Such an advantage has been noted for FI molar diagnosis and the identification of intra-bony defects, dehiscence and fenestration defects (Kasaj & Willershausen 2007). Besides, CBCT facilitates a reduction in treatment costs and time for periodontally involved maxillary molars (Walter et al. 2011).

However, CBCT is somewhat limited in clinical application. For example, the CBCT machine used in this study (3D Accuitomo 60, XYZ Slice View Tomograph; J. Morita) has both a larger imaging area (60×60 mm) and a regular sized area (40×40 mm), expanding the radiographic area compared with its predecessor product. However, it can neither image all of the teeth nor reflect the entire maxilla or mandible with a single scan, as is possible with panoramic imaging. Furthermore, when there is metal in the projection, such as metal crowns or amalgam fillings, artifacts will form and make it difficult to identify the edge of the alveolar bone.

Although CBCT is a promising technology for periodontal diagnosis and treatment planning, its effective radiation doses are still higher than in conventional panoramic and intra-oral imaging (Thilander-Klang & Helmrot 2010, Batista et al. 2012). Like all other diagnostic radiology procedures, CBCT exposes organs and sensitive tissues in the head and neck region, such as the eye lens, thyroid gland, parotid glands and occipital region, to radiation, though the CBCT dose varies substantially depending on the device, field of view and factors of the selected technique (Ludlow et al. 2006). Using a smaller volume that can be restricted to the area of interest, CBCT has a low effective dose. The exposure time of the CBCT device used in this

study is approximately 18 seconds, and the effective dose is only about 1.8 times as high as that of a panoramic X-ray with film exposure. Given that the exposure time is approximately one seventh that of conventional medical CT, the patient radiation dose is also five times lower. Even though such exposure is reduced, it is critical to maintain low levels of radiation exposure for the dental personnel and patients. According to the ALARA (as low as reasonably achievable) principle, dentists must take radiographs of sufficient quality at the lowest possible radiation dose to the patients. We still need to reduce these doses by judicious adjustment of exposure factors and limit the field of view to the smallest dimensions consistent with the clinical situation. Clearly, high-quality research evidence is needed to assess whether the use of CBCT improves patient outcomes. And as additional diagnostic measure, CBCT is justified only when more invasive therapies are planned (Walter et al. 2011).

Conclusions

In this study, CBCT and intra-surgical assessments of maxillary molar FI were found to be in strong agreement. CBCT enables the accurate estimation and classification of FI as well as a visualization of the root morphologies. These measures are essential for a reliable diagnosis and prognosis of the maxillary molars and for adequate treatment planning.

Acknowledgements

The authors would like to thank the members of the Department of Periodontology and Radiology for their help in the current investiga-

tion. The technical assistance of Dr. Cheng Xueyuan in performing the CBCT imaging is highly appreciated. We also acknowledge the help from Dr. Huimei Jia and Dr. Yi Wen.

References

- Batista, W. O., Navarro, M. V. & Maia, A. F. (2012) Effective doses in panoramic images from conventional and CBCT equipment. *Radiation Protection Dosimetry* **151**, 67–75.
- Feijo, C. V., Lucena, J. G., Kurita, L. M. & Pereira, S. L. (2012) Evaluation of cone beam computed tomography in the detection of horizontal periodontal bone defects: an in vivo study. *The International Journal of Periodontics & Restorative Dentistry* **32**, e162–e168.
- Fuhrmann, R. A., Buecker, A. & Diedrich, P. R. (1995) Assessment of alveolar bone loss with high resolution computed tomography. *Journal of Periodontal Research* **30**, 258–263.
- Hamp, S. E., Nyman, S. & Lindhe, J. (1975) Periodontal treatment of multirooted teeth. Results after 5 years. *Journal of Clinical Periodontology* **2**, 126–135.
- Ito, K., Gomi, Y., Sato, S., Arai, Y. & Shinoda, K. (2001) Clinical application of a new compact CT-system to assess 3-D images for the preoperative treatment planning of implants in the posterior mandible. A case report. *Clinical Oral Implants Research* **12**, 539–542.
- Kasaj, A. & Willershausen, B. (2007) Digital volume tomography for diagnostics in periodontology. *International Journal of Computerized Dentistry* **10**, 155–168.
- Landis, J. R. & Koch, G. G. (1977) An application of hierarchical kappa-type statistics in the assessment among multiple observers. *Biometrics* **33**, 363–374.
- Ludlow, J. B., Davies-Ludlow, L. E., Brooks, S. L. & Howerton, W. B. (2006) Dosimetry of 3 CBCT devices for oral and maxillofacial radiology: CB Mercuray, NewTom 3G and i-CAT. *Dentomaxillofacial Radiology* **35**, 219–226.
- Mengel, R., Candir, M., Shiratori, K. & Floresde-Jacoby, L. (2005) Digital volume tomography in the diagnosis of periodontal defects: an in vitro study on native pig and human mandibles. *Journal of Periodontology* **76**, 665–673.
- Misch, K. A., Yi, E. S. & Sarment, D. P. (2006) Accuracy of cone beam computed tomography for periodontal defect measurements. *Journal of Periodontology* **77**, 1261–1266.
- Pihlstrom, B. L. (2001) Periodontal risk assessment, diagnosis and treatment planning. *Periodontology 2000* **25**, 37–58.
- Pinsky, H. M., Dyda, S., Pinsky, R. W., Misch, K. A. & Sarment, D. P. (2006) Accuracy of three-dimensional measurements using cone-beam CT. *Dentomaxillofacial Radiology* **35**, 410–416.
- Santana, R. B., Uzel, M. I., Gusman, H., Gunaydin, Y., Jones, J. A. & Leone, C. W. (2004) Morphometric analysis of the furcation anatomy of mandibular molars. *Journal of Periodontology* **75**, 824–829.
- Thilander-Klang, A. & Helmrot, E. (2010) Methods of determining the effective dose in dental radiology. *Radiation Protection Dosimetry* **139**, 306–309.
- Vandenbergh, B., Corpas, L., Bosmans, H., Yang, J. & Jacobs, R. (2011) A comprehensive in vitro study of image accuracy and quality for periodontal diagnosis. Part 1: the influence of X-ray generator on periodontal measurements using conventional and digital receptors. *Clinical Oral Investigations* **15**, 537–549.
- Vandenbergh, B., Jacobs, R. & Yang, J. (2007) Diagnostic validity (or acuity) of 2D CCD versus 3D CBCT-images for assessing periodontal breakdown. *Oral Surgery Oral Medicine Oral Pathology Oral Radiology and Endodontology* **104**, 395–401.
- Walter, C., Kaner, D., Berndt, D. C., Weiger, R. & Zitzmann, N. U. (2009) Three-dimensional imaging as a pre-operative tool in decision making for furcation surgery. *Journal of Clinical Periodontology* **36**, 250–257.
- Walter, C., Weiger, R., Dietrich, T., Lang, N. P. & Zitzmann, N. U. (2011) Does three-dimensional imaging offer a financial benefit for treating maxillary molars with furcation involvement? A pilot clinical case series. *Clinical Oral Implants Research* **23**, 351–358.
- Walter, C., Weiger, R. & Zitzmann, N. U. (2010) Accuracy of three-dimensional imaging in assessing maxillary molar furcation involvement. *Journal of Clinical Periodontology* **37**, 436–441.
- Zhong, J. S., Ou-Yang, X. Y., Liu, D. G. & Cao, C. F. (2010) Evaluation of the in vitro quantitative measurement of II degree furcation involvements in mandibular molars by cone-beam computed tomography. *Beijing Da Xue Xue Bao* **42**, 41–45.

Address:
Changzhou Sun
100034 Xishenku Avenue Jia 37
Xicheng District
Beijing
China
E-mail: ChangzhouSun66@126.com

Clinical Relevance

Scientific rationale for the study: Conventional clinical methodologies for the assessment of the FI of maxillary molars do not provide sufficient information for the best possible clinical diagnosis and treatment planning. This study

aimed to investigate the accuracy of CBCT, a thorough and detailed three-dimensional application, in assessing maxillary molar FI. *Principal findings:* Intra-surgical findings confirmed 82.4% of the CBCT data. The three-dimensional measurements of the FI by CBCT were

confirmed by the intra-surgical values. Bone loss was underestimated, but no more than 0.5 mm. *Practical implications:* CBCT can be used for reliable diagnosis, prognosis and treatment planning of maxillary molars.