

Sialography of the Transplanted Submandibular Gland

JIA-ZENG SU, DDS,¹ XIAO-JING LIU, MD,¹ DENG-GAO LIU, DDS, MD,² WEN-GE REN, BS,² AND GUANG-YAN YU, DDS, PHD¹

ABSTRACT Autologous transplantation of submandibular gland (SMG) is effective for severe keratoconjunctivitis sicca (KCS). Sialography is a method for morphological evaluation of the transplanted gland. We recruited 15 patients (15 eyes) with severe KCS who had successfully undergone SMG transplantation. Thirteen patients had normal transplanted SMGs, while two patients were suspected to have obstructive sialadenitis of the transplanted SMG. Sialography was performed in each patient with meglumine diatrizoate. Projections were applied immediately and 5, 7, and 10 min after contrast injection. The median dose of the contrast medium was 0.9 ml (range, 0.7–1.1 ml) for the full-size transplanted SMGs and 0.5 ml for the glands after reduction surgery. The acini and the ducts were clearly visible on sialograms. The contrast medium was completely excreted in 10 min in normal transplanted SMGs. The main duct had a regular shape in normal transplanted SMGs, while irregular dilation and stricture of the duct with delayed excretion of the contrast medium were found in the glands with obstructive sialadenitis. In conclusion, sialography is

clinically feasible and valuable for the morphological evaluation of the transplanted SMG.

KEY WORDS keratoconjunctivitis sicca, morphology, sialadenitis, sialography, submandibular gland, transplantation

I. INTRODUCTION

Keratoconjunctivitis sicca (KCS) is a multifactorial disease of the tears and ocular surfaces that results in discomfort, visual disturbance, and tear film instability with possible damage to the ocular surface.¹ The severe form of KCS had no effective treatment before the advent of microvascular autologous transplantation of the submandibular gland (SMG).² SMG transplantation with insertion of Wharton's duct into the upper conjunctival fornix provides a continuous, endogenous source of ocular lubrication and offers a good prognosis in severe KCS.²⁻⁷ The secretory function of the transplanted SMG can be evaluated by several methods.^{8,9} However, to our knowledge, there is no literature referring to the morphological evaluation of the transplanted SMG.

In most patients who have undergone SMG transplantation, the transplanted gland shows normal secretion, and the symptoms of dry eye are obviously relieved.²⁻⁷ However, in some patients, the transplanted SMG produces little and viscous secretion, which is very similar to the secretion in chronic obstructive parotitis, and the symptoms of dry eye are not relieved.^{6,10}

Sialography is one of the main techniques for the morphological evaluation of major salivary glands and for the diagnosis of chronic obstructive parotitis and Sjögren syndrome. For the first time, the present study applied sialography to assess the radiographic anatomy of the transplanted SMG and investigated the role of this technique in the diagnosis of obstructive sialadenitis of transplanted SMGs.

II. PATIENTS AND MATERIALS

This study was approved by the Ethics Committee for Human Experiments at Peking University and was in accordance with the Declaration of Helsinki guidelines for human

Accepted for publication February 2014.

From the ¹Department of Oral and Maxillofacial Surgery, and the ²Department of Oral Radiology, Peking University School and Hospital of Stomatology, Beijing, P. R. China.

This study was supported by grants from the National Natural Science Foundation of China (No. 81271161), the Ministry of Education (No. 20120001110045), and Beijing Natural Science Foundation (No. 7132201). The funding organization had no role in the design or conduct of this research.

The authors have no proprietary or commercial interests in any concept or product discussed in this article.

Single-copy reprint requests to Prof. Guang-Yan Yu, Department of Oral and Maxillofacial Surgery, Peking University School of Stomatology, 22 Zhong Guan Cun South St., Beijing 100081, P. R. China.

Corresponding author: Prof. Guang-Yan Yu, DDS, PhD, Department of Oral and Maxillofacial Surgery, Peking University School of Stomatology, Beijing 100081, P. R. China. Tel: 86-10-82195245. Fax: 86-10-62173402. E-mail address: gyyu@263.net

© 2014 Elsevier Inc. All rights reserved. *The Ocular Surface* ISSN: 1542-0124. Su JZ, Liu XJ, Liu DG, Ren WG, Yu GY. Sialography of the transplanted submandibular gland. 2014;12(3):215-220.

OUTLINE

- I. Introduction
- II. Patients and Materials
- III. The Sialography Procedure
- IV. Sialographic Findings in Normal Transplanted SMGs
- V. Sialographic Findings in Transplanted SMGs with Chronic Sialadenitis
- VI. Practicability of Sialography of the Transplanted SMG
- VII. Conclusion

research. All patients provided informed consent prior to participation in this study.

Of 51 patients with severe KCS who successfully underwent microvascular autologous SMG transplantation in Peking University School of Stomatology and were followed up between December 2008 and May 2013, we randomly selected five patients each at three different time points in their follow-up (3 months, 9 months, and >1 year after the operation). Thus, in total, 15 patients (7 males, median age=26 years, range=13–40 years; and 8 females, median age=30 years, range=17–57 years) were included in this study. The left eye was involved in 10 patients, and the right eye was involved in 5 patients. Before SMG transplantation, all 15 patients were diagnosed with severe KCS; they had obvious and persistent dry eye symptoms, and previous ophthalmologic treatment had been ineffective in these patients. During the postoperative follow-up, 13 transplanted glands showed sufficient and clear secretion. In these 13 patients, the symptoms of dry eye disappeared or were obviously relieved. In addition, the Schirmer test values increased, and measurements of tear film breakup time and corneal fluorescein staining showed that the ocular surface condition had improved (Table 1). However, two glands had recurrent swelling and produced only little and viscous secretion (Table 1); these patients were suspected to have developed chronic obstructive sialadenitis.

The secretory function of the submandibular glands was evaluated using ^{99m}Tc pertechnetate scintigraphy. The salivary uptake ratios and excretion fractions before and after surgery were calculated (Table 1).¹¹ Glands with abnormal secretion showed marked decrease in the pertechnetate excretion fraction.

All the transplanted SMGs in the study were vital, as confirmed by ^{99m}Tc scintigraphy. Transplanted SMGs with acute inflammation were excluded from the study.

Meglumine diatrizoate was used as a contrast medium and injected via a polyethylene tube (outside diameter, 0.6 mm; Becton, Dickinson and Company, Franklin Lakes, NJ, USA). Sialography was performed in an Orthopantomograph OP100 panoramic radiography unit (Instrumentarium Imaging, Tuusula, Finland).

III. THE SIALOGRAPHY PROCEDURE

The orifice of Wharton's duct in the upper conjunctival fornix was identified, and the duct was cannulated with approximately 3 cm of a polyethylene tube (Figure 1A). The

cannulation of Wharton's duct is a widely applied technique in SMG transplantation.^{5,6} Gentle massage of the gland usually rendered the orifice of the duct clear.

Meglumine diatrizoate was chosen as the radio-opaque agent, to avoid over-stagnation; as a water-soluble contrast medium, meglumine diatrizoate might be more easily discharged than an oil-based medium. Moreover, the long-term safety of meglumine diatrizoate for investigations of the eye has been confirmed.¹² Meglumine diatrizoate was injected into the transplanted gland via the tube (Figure 1B). Injection was terminated when a feeling of mild distension of the transplanted SMG was reported by the patient. The median dose of the contrast medium was 0.9 ml (range, 0.7–1.1 ml) in 11 patients who had the full-size transplanted SMGs. In the four patients who had undergone reduction surgery, as described by Geerling et al,² the injection doses were 0.4, 0.5, 0.5, and 0.5 ml. We required that the injection of an adequate dose of the contrast medium was indicated by the feeling of a mild swelling of the transplanted SMG.

Lateral and anteroposterior projections were applied immediately following the injection, using 77 kV and 16 mA (Figure 1C and D). The scan time was 0.5 s for the lateral projection and 0.8 s for the anteroposterior projection. The patients were then asked to do some exercises (climbing 6 flights of stairs) to help promote evacuation of the contrast medium, and projections were repeated 5, 7, and 10 min later to evaluate the excretory function of the transplanted SMG.

IV. SIALOGRAPHIC FINDINGS IN NORMAL TRANSPLANTED SMGS

Sialography was completed in all 15 study patients without any adverse reactions or severe discomfort. Normal transplanted SMGs appeared well filled with the contrast medium and were clearly visible on sialograms. The body of the gland was marked by an opacity and depiction of the secretory duct showed smooth walls and a regular shape (Figure 2). The median width and length of the main duct in lateral sialograms were 4 mm and 5 cm, respectively. The distal part of the main duct (between the lateral orbital wall and the ductal orifice) was demonstrated more clearly in anteroposterior sialograms than in lateral sialograms (Figure 2B).

The location of the gland body as well as the form of the main duct varied considerably depending on the surgical arrangement during transplantation, and the transplanted SMGs with reduction surgery showed typical changes on lateral sialograms. Only the remaining acini near the main duct was visible in these glands (Figure 2C).

Residual meglumine diatrizoate was visible at both 5 and 7 min after injection (Figure 3). The contrast medium was excreted completely from the transplanted SMG in 10 min, which is longer than that in normal parotid glands or nontransplanted SMGs. A possible explanation for this finding is that the capacity for saliva secretion declined after SMG transplantation.¹⁰

Table 1. Information on operated eyes and submandibular glands (SMGs) before and after transplantation

Case No.	Before transplantation					After transplantation				
	ST (mm)	TFBUT (sec)	FS	UR	EF (%)	ST (mm)	TFBUT (sec)	FS	UR	EF (%)
1	0	0	12	2.1	18.7	10	2	10	1.8	16.9
2	0	0	10	0.8	17.8	12	0	8	0.6	15.2
3	0	0	6	1.2	43.2	13	1	4	1.0	49.4
4	1	0	12	4.1	51.2	30	2	8	3.3	45.7
5	0	0	12	3.8	37.7	35	0	8	1.5	32.8
6	1	0	12	1.4	25.2	5	2	6	1.2	21.8
7	0	0	12	2.2	31.0	15	0	8	2.6	37.8
8	0	0	8	6.5	63.5	65	0	6	4.6	62.0
9	0	0	12	6.4	40.0	64	3	10	5.1	26.2
10	0	0	12	3.1	47.6	45	2	8	2.4	45.8
11	2	0	12	4.6	50.3	19	0	12	4.5	47.0
12	0	0	12	0.4	36.9	14	6	4	0.4	28.6
13	0	0	6	1.0	44.4	11	0	4	0.8	25.7
14*	1	0	12	0.2	28.1	2	0	12	3.2	0.4
15*	0	0	12	2.4	29.5	5	0	10	1.5	10.9

* patients with abnormal secretion of the transplanted SMG.

ST, Schirmer test; TFBUT, tear film breakup time; FS, fluorescent staining; UR, Uptake ratios of the SMG; EF, excretion fractions of the SMG.

V. SIALOGRAPHIC FINDINGS IN TRANSPLANTED SMGS WITH CHRONIC SIALADENITIS

The two glands that underwent recurrent swelling and produced little and viscous secretion showed a different appearance on sialography than the 13 normal transplanted glands. Their cardinal feature was irregular dilation and stricture of the main duct, which formed a “sausage-like” pattern (Figure 4). The maximum diameter of the main duct was obviously larger than that of the main ducts of the normal

glands. The excretion function of these SMGs declined significantly, as a large amount of contrast medium was retained in the ducts 10 min after contrast injection (Figure 4). These findings were very similar to the sialographic appearance of chronic obstructive parotitis. Thus, sialography confirmed our clinical suspicion of chronic obstructive sialadenitis of the transplanted SMG in these two patients. This indicates that sialography could provide important morphological evidence for the diagnosis of chronic sialadenitis of the

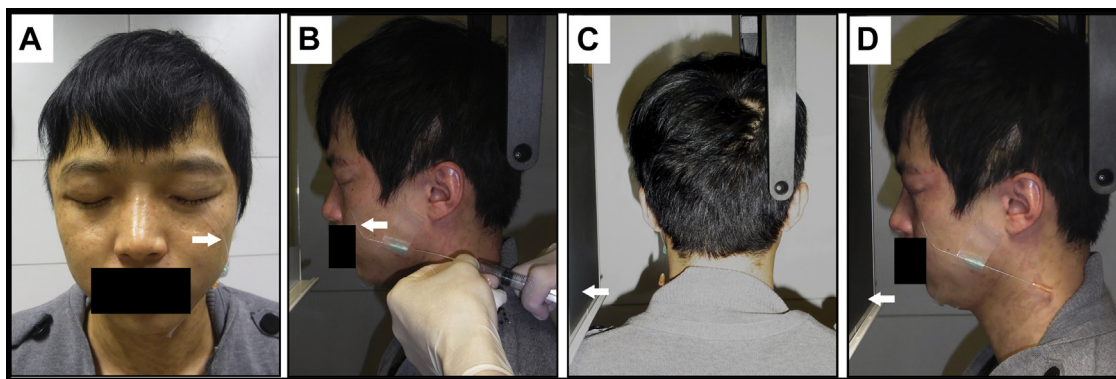


Figure 1. Sialography procedure. (A) The main duct of the transplanted submandibular gland was cannulated with a polyethylene tube (arrow), which was fixed on the face. (B) Meglumine diatrizoate was injected via the tube (arrow). (C) Lateral projection was applied with the subject seated in a radiography unit (arrow: the Flat Panel Detector). (D) Anteroposterior projection was applied (arrow: the Flat Panel Detector).

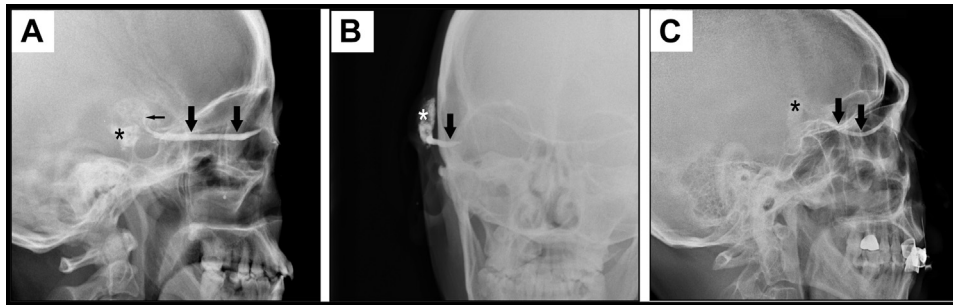


Figure 2. Normal anatomy of the transplanted submandibular gland. (A) In lateral sialograms, the body of the gland (*) was marked by an opacity in the anterior and lower regions of the temporal squama. The terminal duct branches converged into larger (secondary) ducts (arrows) and finally the main duct (bold arrows). The main duct exited the transplanted gland from its anterior border, lay straight across the sphenoid bone and the frontal process of the zygomatic bone and terminated in front of the lateral orbital wall. (B) In anteroposterior sialograms, the gland body (*) was located in the soft tissue above the zygomatic bone, outside the temporal squama. The distal part of the main duct (bold arrow) was clearly demonstrated. (C) For a transplanted gland after reduction surgery, only the remaining acini (*) near the main duct (bold arrows) was visible.

transplanted SMG. No obvious change was seen in the secondary ducts in the transplanted SMGs with obstructive sialadenitis. A possible explanation for this finding is that due to the short duration of symptoms and early phase of sialadenitis, the secondary ducts had not yet been affected. Another explanation is that the secretory function of these transplanted SMGs never recovered due to the onset of ductal obstruction, and therefore, the pressure from saliva stasis was not high enough to dilate the secondary ducts.

VI. PRACTICABILITY OF SIALOGRAPHY OF THE TRANSPLANTED SMG

SMG transplantation is an effective treatment for patients with severe KCS.¹³ However, clinically abnormal secretion of the transplanted glands occurs in some patients.^{6,10} In these patients, Schirmer test and ^{99m}Tc scintigraphy show decreased secretion function of the transplanted SMG. However, a practical morphological evaluation method is required. Sialography is the gold standard for

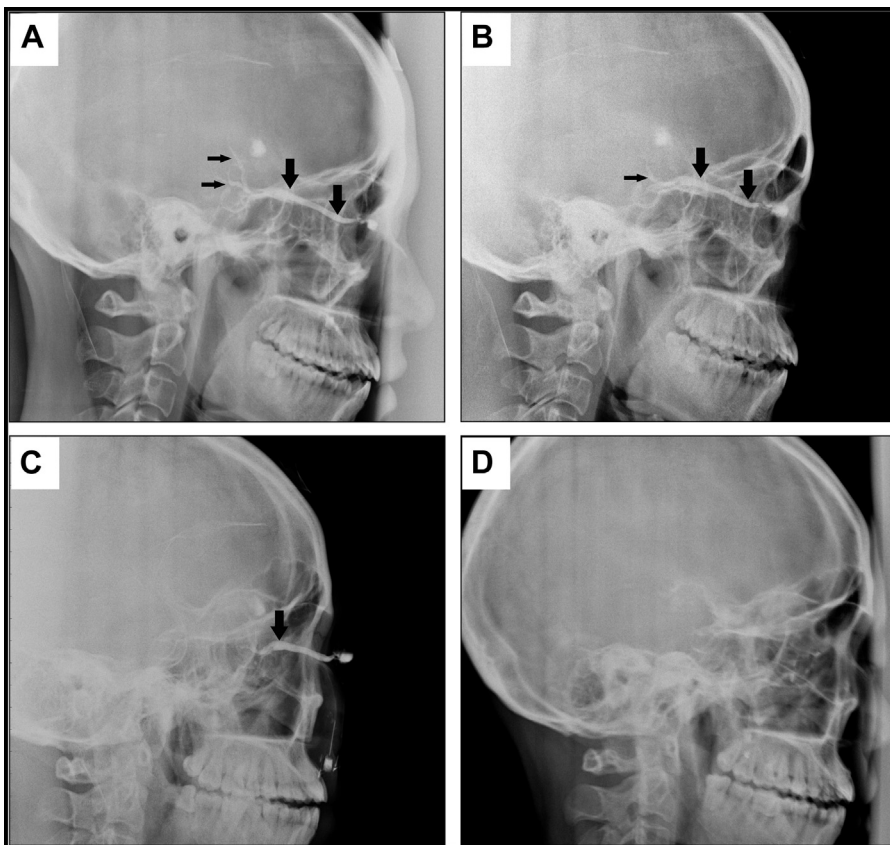


Figure 3. Excretion function of the normal transplanted submandibular gland. (A) Both the secondary duct (arrows) and the main duct (bold arrows) were well filled with the meglumine diatrizoate immediately after injection. Residual contrast medium was still visible (B) 5 and (C) 7 min after injection. (D) Ten min after injection, the contrast medium was excreted completely in sialogram.

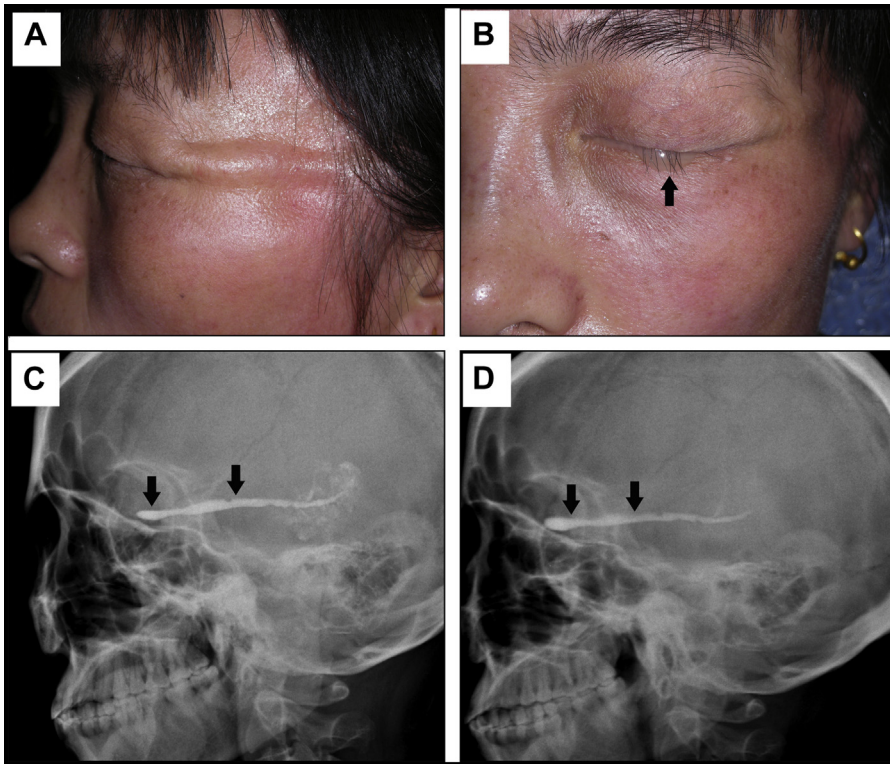


Figure 4. Abnormal secretion and sialographic changes in a transplanted submandibular gland with obstructive sialadenitis. (A) Swelling of the main duct. (B) Little and viscous discharge (arrow). (C) Irregular dilation and stricture of the main duct (arrows). (D) Residual contrast medium (arrows) 10 min after injection.

the diagnosis of chronic obstructive parotitis.^{14,15} The results of our study showed that sialography could be used as a simple and safe technique to clearly show the morphology of the transplanted SMG, especially the structures of the main duct. For patients with abnormal secretion of the transplanted SMG, sialography can not only diagnose obstructive sialadenitis but can also provide details of the location and severity of the ductal lesion, which are indispensable for formulation of the treatment plan.

In recent years, magnetic resonance (MR) sialography using T2-weighted sequences for monitoring liquids has been suggested as an alternative technique for the imaging of ductal salivary gland diseases.¹⁵ MR sialography is superior to sialography in some aspects. It is noninvasive, involves no ionized radiation, and does not require cannulation or iodinated contrast injection.¹⁵ However, because of its higher spatial resolution, sialography could provide superior diagnostic information as compared with that provided by MR sialography.¹⁶ Many researchers have used sialography to examine the fine anatomy and morphology of the salivary ductal system.¹⁷⁻²⁰ As MR sialography is not yet an established technique,²⁰ sialography continues to be the standard technique for imaging the duct system.¹⁶

Sialography requires cannulation of the duct and injection of iodinated contrast material.^{15,16} When used for patients with transplanted SMGs, sialography requires cannulation in the upper lateral conjunctival fold, which is a commonly applied and safe procedure in SMG

transplantation.^{5,6} The long-term safety of the use of the contrast medium meglumine diatrizoate for investigations of the eye has been confirmed.¹² Therefore, sialography of the transplanted SMG is safe for clinical application. This procedure was well tolerated by the patients in the present study.

Because of the need for iodinated contrast agents, sialography is contraindicated in patients with iodine allergy. In such patients, MR sialography provides an excellent alternative.¹⁶

VII. CONCLUSION

Sialography of the transplanted SMG is clinically feasible and can provide important morphological evidence for the diagnosis of chronic obstructive sialadenitis of the transplanted SMG.

REFERENCES

1. Lemp MA, Baudouin C, Baum J, et al. The definition and classification of dry eye disease: Report of the Definition and Classification Subcommittee of the international Dry Eye Workshop (2007). *Ocul Surf* 2007;5:75-92
2. Geerling G, Sieg P, Bastian GO, Laqua H. Transplantation of the autologous submandibular gland for most severe cases of keratoconjunctivitis sicca. *Ophthalmology* 1998;105:327-35
3. Borrelli M, Schroder C, Dart JK, et al. Long-term follow-up after submandibular gland transplantation in severe dry eyes secondary to cicatrizing conjunctivitis. *Am J Ophthalmol* 2010;150:894-904
4. Jacobsen HC, Hakim SG, Lauer I, Dendorfer A, et al. Long-term results of autologous submandibular gland transfer for the surgical treatment of severe keratoconjunctivitis sicca. *J Craniomaxillofac Surg* 2008;36:227-33

5. Paniello RC. Submandibular gland transfer for severe xerophthalmia. *Laryngoscope* 2007;117:40-4
6. Yu GY, Zhu ZH, Mao C, et al. Microvascular autologous submandibular gland transfer in severe cases of keratoconjunctivitis sicca. *Int J Oral Maxillofac Surg* 2004;33:235-9
7. Qin J, Zhang L, Cai ZG, et al. Microvascular autologous transplantation of partial submandibular gland for severe keratoconjunctivitis sicca. *Br J Ophthalmol* 2013;97:1123-8
8. Su JZ, Liu XJ, Zhang L, Yu GY. Schirmer test in transplanted submandibular gland: influencing factors and a modified measurement method. *Cornea* 2013;32:419-22
9. Zhang L, Zhu ZH, Dai HJ, et al. Application of 99mTc-pertechnetate scintigraphy to microvascular autologous transplantation of the submandibular gland in patients with severe keratoconjunctivitis sicca. *J Nucl Med* 2007;48:1431-5
10. MacLeod AM, Robbins SP. Submandibular gland transfer in the correction of dry eye. *Aust N Z J Ophthalmol* 1992;20:99-103
11. Zou Q, Jiao J, Zou MH, et al. Semi-quantitative evaluation of salivary gland function in Sjogren's syndrome using salivary gland scintigraphy. *Clin Rheumatol* 2012;31:1699-705
12. Munk PL, Burhenne LW, Buffam FV, Nugent RA, et al. Dacryocystography: comparison of water-soluble and oil-based contrast agents. *Radiology* 1989;173:827-30
13. Pflugfelder SC, Geerling G, Kinoshita S, et al. Management and therapy of dry eye disease: Report of the Management and Therapy Subcommittee of the international Dry Eye WorkShop (2007). *Ocul Surf* 2007;5:163-78
14. Harbison JM, Liess BD, Templer JW, Zitsch 3rd RP, et al. Chronic parotitis: a challenging disease entity. *Ear Nose Throat J* 2011;90:E13-6
15. Karaca Erdogan N, Altay C, Ozenler N, et al. Magnetic resonance sialography findings of submandibular ducts imaging. *Biomed Res Int* 2013;2013:417052
16. Kalinowski M, Heverhagen JT, Rehberg E, Klose KJ, et al. Comparative study of MR sialography and digital subtraction sialography for benign salivary gland disorders. *AJNR Am J Neuroradiol* 2002;23:1485-92
17. Hasson O. Modern sialography for screening of salivary gland obstruction. *J Oral Maxillofac Surg* 2010;68:276-80
18. Mehanna H, McQueen A, Robinson M, Paleri V. Salivary gland swellings. *Clin Otolaryngol* 2013;38:58-65
19. Horsburgh A, Massoud TF. The role of salivary duct morphology in the aetiology of sialadenitis: statistical analysis of sialographic features. *Int J Oral Maxillofac Surg* 2013;42:124-8
20. Burke CJ, Thomas RH, Howlett D. Imaging the major salivary glands. *Br J Oral Maxillofac Surg* 2011;49:261-9