

# Paraneoplastic pemphigus characterized by polymorphic oral mucosal manifestations— Report of two cases

Zhimin Yan, DDS, PhD<sup>1</sup>/Hong Hua, DDS, PhD<sup>2</sup>/Yan Gao, DDS, PhD<sup>3</sup>

Paraneoplastic pemphigus is a rare autoimmune disease characterized by polymorphous mucocutaneous lesions in association with underlying neoplasia. We report two Chinese patients, one with chronic lymphocytic leukemia and the other with thymoma. Both of them initially presented with severe oral erosion with lichenoid features that resisted all the regular therapy. The routine histology was not typical in both patients, with features of liquefaction degeneration of the basal cell layer and subbasilar lymphocytic infiltration. Important differential diagnoses for the two cases include lichenoid eruption secondary to chemotherapy, pemphigus, and pemphigoid. Immunohistologic testing played an essential role in the diagnoses. Direct immunofluorescence shows both intercellular and basement membrane deposition of immunoreactants. Indirect immunofluorescence using rat bladder as the substrate has been shown to be an inexpensive and reliable diagnostic tool. Our patients' clinical and immunopathologic features were consistent with a diagnosis of paraneoplastic pemphigus, a special subset of pemphigus. Patients' conditions were improved after high-dose systemic corticosteroid therapy after underlying malignancies were treated. (*Quintessence Int* 2010;41:689–694)

**Key words:** diagnosis, direct immunofluorescence, indirect immunofluorescence, oral presentation, paraneoplastic pemphigus

Paraneoplastic pemphigus (PNP), an autoimmune blistering and erosive mucocutaneous disease, is an extremely rare but severe subset of pemphigus. It was first defined as a separate entity in 1990 by Anhalt et al for its definite association with malignancy.<sup>1</sup> Since then, approximately 200 cases have been reported worldwide. PNP is particularly important in oral medicine because all cases have oral mucosa involvement, and 45% have oral erosions as the first sign.

This report presents two Chinese patients with underlying leukemia and thymoma, respectively, who manifested with extensive polymorphic oral mucosa lesions. Differential diagnosis included bullous pemphigoid, lichen planus, pemphigus vulgaris, erythema multiforme, Stevens-Johnson syndrome, or a variable combination of these entities. Both patients were eventually diagnosed with PNP based on the clinical and laboratory examination.

<sup>1</sup>Department of Oral Medicine, Peking University School of Stomatology, Beijing, China; Division of Orofacial Pain, Department of Diagnostic Sciences, University of Medicine and Dentistry of New Jersey, New Jersey Dental School, Newark, New Jersey.

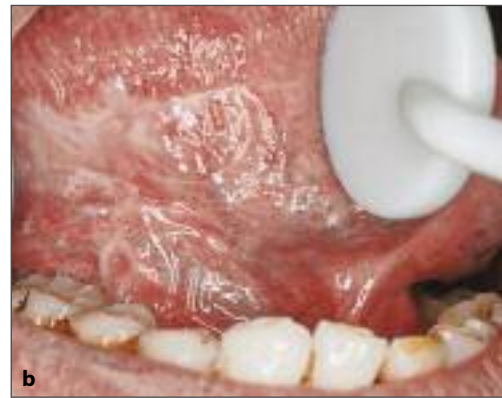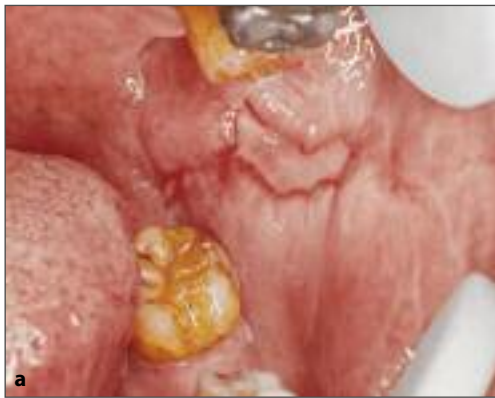<sup>2</sup>Professor, Department of Oral Medicine, Peking University School of Stomatology, Beijing, China.

<sup>3</sup>Professor and Chair, Department of Oral Pathology, Peking University School of Stomatology, Beijing, China.

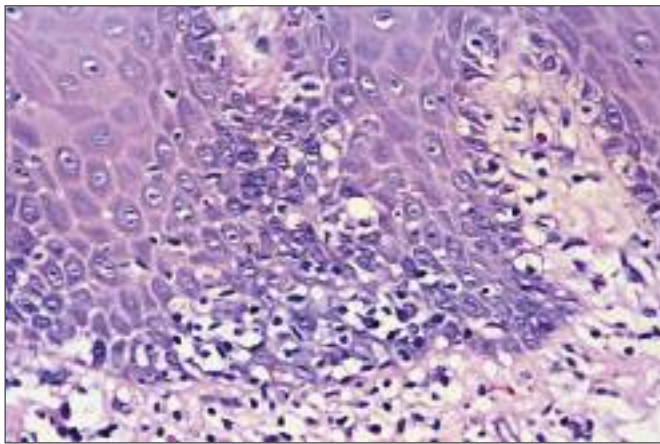
**Correspondence:** Dr Hong Hua, Department of Oral Medicine, Peking University School of Stomatology, 22 South Zhongguancun Street, Haidian District, Beijing 100081, China. Fax: 86-10-6217-3402. Email: honghua1968@yahoo.com.cn

## CASE 1

A 65-year-old man had been diagnosed with chronic lymphocytic leukemia and received chemotherapy in July 2003. Two months later, he complained of difficulty with intake of food due to painful oral ulcer. The oral lesions progressed despite topical treatment, and the patient was referred to the dental center for further evaluation and management. Oral examinations revealed bilateral exudative



**Fig 1** Oral manifestations of the first patient. (a) Exudative erosion on the buccal mucosa with peripheral white striations. (b) Lichenoid reticular pattern on ventral tongue.

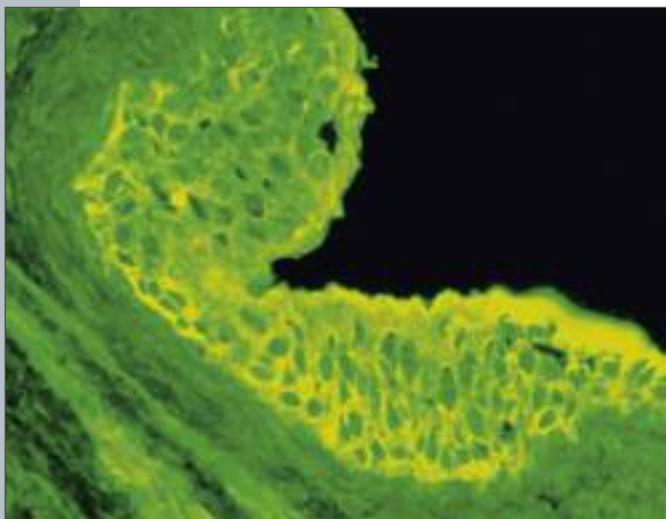


**Fig 2** Histologic examination of buccal mucosa showed liquefaction degeneration of the basal cell layer and subbasilar lymphocytic infiltration (hematoxylin-eosin; original magnification  $\times 40$ ).

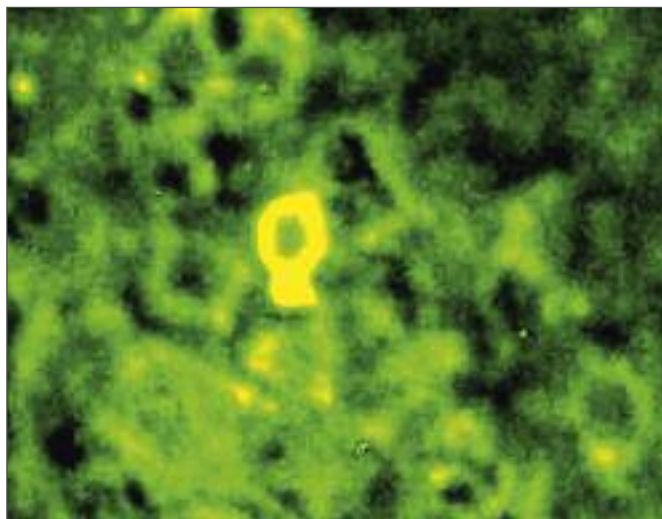
erosion on the buccal mucosa, with peripheral striations (Fig 1a). Lichenoid reticular pattern formed by white striations can be observed bilaterally on the ventrolateral tongue (Fig 1b). The initial diagnosis was lichenoid eruptions due to prior chemotherapy. The patient's symptoms improved with topical steroid (dexamethasone) and gentamicin oral rinse, but his oral lesions did not heal.

In July 2004, he suffered from blistering, papular eruption on his trunk. Physical examinations revealed a polymorphous eruption that included lichenoid plaques as well as bullae. Histopathologic examinations of cutaneous biopsies demonstrated intraepithelial as well as subepithelial bullae associated with interface dermatitis. This made it difficult to distinguish histopathologically between pemphigus and pemphigoid. A perilesional biopsy of buccal mucosa revealed "liquefaction degeneration" of the basal cell layer with subbasilar

lymphocytic infiltration consistent with lichenoid eruption (Fig 2). Laboratory investigations revealed negative titers for antinuclear antibody. Enzyme-linked immunosorbent assays (ELISAs) showed the presence of anti-intercellular antibodies against desmoglein 1 and 3 (Dsg-1 and Dsg-3) and high titers of circulatory antibodies at 1:320. As paraneoplastic pemphigus was suspected, an indirect immunofluorescence test was performed using multiple epithelial substrates (rat bladder, esophagus, and small intestine). The patient's serum showed circulating antibodies against intercellular space with bright fluorescence (Fig 3). Direct immunofluorescence using cytological smear as substrates shows immunoglobulin G (IgG) deposition in the intercellular spaces (Fig 4). Reexamination of the skin and mucosa specimen histologically and the result of direct immunofluorescence were, in retrospect, compatible with the diagnosis of PNP.



**Fig 3** Indirect immunofluorescence using rat bladder as the substrate showed both intercellular and basement membrane deposition of IgG (original magnification  $\times 40$ ).



**Fig 4** Direct immunofluorescence using cytologic smear as substrates showed IgG deposition in the intercellular spaces.

The patient was treated with prednisolone 45 mg (patient body weight about 65 kg) per day, supplemented with traditional Chinese medicines. His cutaneous lesions healed about 2 weeks later, and the buccal mucosa and lips showed great improvement. Prednisolone dosage was slowly tapered down. The patient was symptom-free until December 2004. The oral lesions came back and progressed into unusual extensive erosions affecting lips and the entire oral mucosa. After treatment with prednisone 60 mg per day, the severe oral erosions were under control. The patient was then managed with topical treatment and continued follow-up with the physician for control of leukemia.

## CASE 2

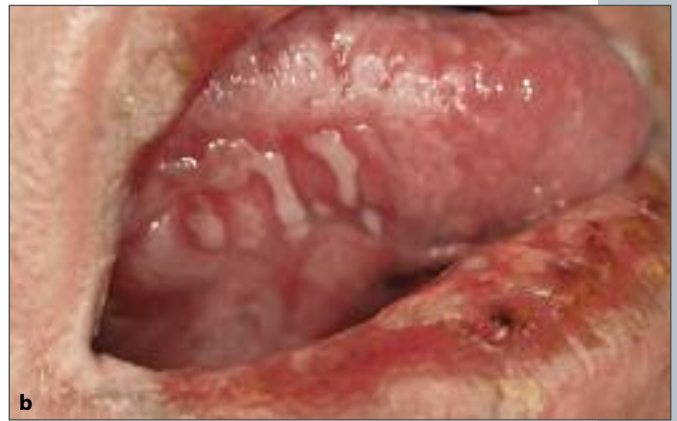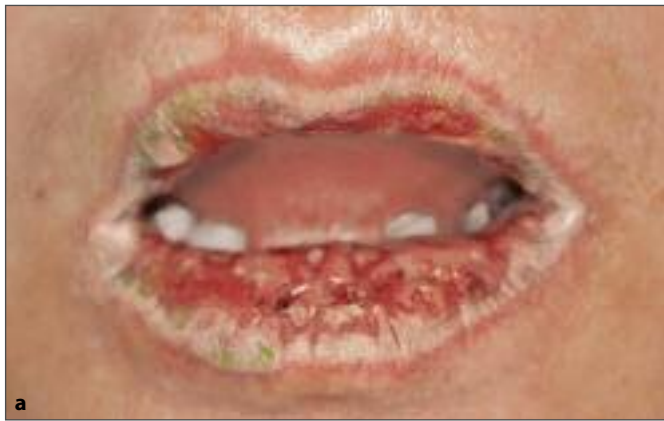In January 2005, a 54-year-old woman was referred to our department with extensive and painful oral erosions. One year before presentation, she was diagnosed with thymoma based upon computed tomography and biopsy. Her tumor was under control after two courses of chemotherapy, using cyclophosphamide and cisplatin. However, 7 months later, she developed blistering, erosive oral

lesions that worsened despite various topical treatments.

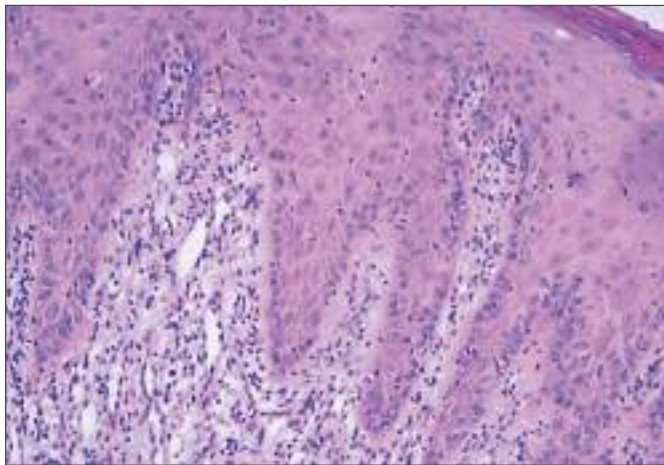
On clinical examination, the patient had blood-crusts on lips and polymorphic oral lesions. Oral erosions were generalized, superficial, and symptomatic (Fig 5). In ELISA studies, anti-intercellular antibodies to Dsg-1 and Dsg-3 could not be detected in serum samples of this patient. A mucosal biopsy from the tongue revealed "liquefaction degeneration" of the basal cell layer with few acantholytic cells, basal vacuolization, and no suprabasal bullae (Fig 6). Direct immunofluorescence of perilesional tissue disclosed deposits of IgG and C3 in the intercellular spaces. Indirect immunofluorescence, using rat urinary bladder, esophagus, and small intestine as substrates, revealed circulating antibodies against intercellular spaces and basement membrane (Fig 7). The diagnosis of PNP was made based upon the patient's remarkable medical history and polymorphic oral manifestations, combined with characteristic histologic and immunopathologic features.

The patient was first treated with topical corticosteroids and nystatin. It did help in achieving some improvement. She was also encouraged to perform frequent oral rinse, as well as normal saline soaks over the lips

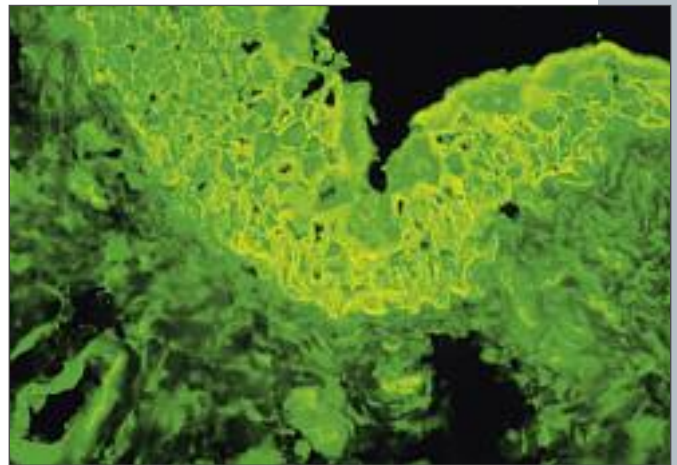




**Fig 5** Oral manifestations of the second patient. (a) Extensive erosions covered with hemorrhagic crust with peripheral striations. (b) Painful erosions on ventral tongue.



**Fig 6** Mucous biopsy of the tongue revealed liquefaction degeneration of the basal cell layer, but no suprabasal bullae were detected (hematoxylin-eosin; original magnification  $\times 40$ ).



**Fig 7** Indirect immunofluorescence using rat urinary bladder as substrates revealed circulating antibodies against intercellular spaces and basement membrane.

followed by mupirocin ointment. Her condition improved significantly after treatment with high doses of prednisone (60 mg/day). There was a complete remission of the mucosal erosions 1 month later. No recurrence was detected on follow-up after 6 months.

## DISCUSSION

PNP was first described by Anhalt in 1990,<sup>1</sup> and the association between PNP and malignancy has been well known for decades. This clinically and immunologically distinct disease is seen principally in aged adults between 45 and 70 years with a near equal gender

distribution. Definitive statistics on the incidence and prevalence is presently not available for its rarity. It often leads to severe oral erosions resembling the features of pemphigus, pemphigoid, or lichenoid drug eruptions and creating a diagnostic dilemma. The possibility of PNP should be borne in mind, especially if malignancy is a suspected cause.

## Etiology

The etiology of PNP is still unknown. Antibodies against Dsg-1 and Dsg-3, antigens for the classic types of pemphigus, have been reported to play an important role in the initial stage of PNP.<sup>2</sup> The immunoprecipitation studies have disclosed presence of autoantibodies against four epithelial

**Table 1 Diagnostic criteria of PNP<sup>8</sup>**

Major criteria	Minor criteria
<ul style="list-style-type: none"> <li>Polymorphous mucocutaneous eruption</li> </ul>	<ul style="list-style-type: none"> <li>Positive cytoplasmic staining of rat bladder epithelium by indirect immunofluorescence</li> </ul>
<ul style="list-style-type: none"> <li>Concurrent internal neoplasia</li> </ul>	<ul style="list-style-type: none"> <li>Intercellular and basement membrane zone immunoreactants on direct immunofluorescence of perilesional tissue</li> </ul>
<ul style="list-style-type: none"> <li>Characteristic serum immunoprecipitation findings</li> </ul>	<ul style="list-style-type: none"> <li>Acantholysis in biopsy specimen from at least one anatomical site of involvement</li> </ul>

polypeptides in patients with PNP. They have an estimated molecular weight of 250, 230, 210, and 190 kilodaltons (kDa), representing desmoplakin 1, bullous pemphigoid antigen, desmoplakin 2/envoplakin doublet, and periplakin, respectively.<sup>3,4</sup> In 2004, Wang et al detected autoantibodies secreted by cultured tumor cells reacting against epidermal proteins. These autoantibodies could be an essential factor in PNP pathogenesis.<sup>5</sup>

**Clinical features**

Clinically, PNP is characterized by polymorphic mucocutaneous lesions resembling lesions of bullous pemphigoid, lichen planus, pemphigus vulgaris, erythema multiforme, Stevens-Johnson syndrome, or a variable combination of these entities. Nearly all patients with PNP typically have predominant mucosal involvement, and 45% of them initially present with isolated oral erosions that might be a sign of the underlying neoplasm. It is especially important since some patients with PNP have not been diagnosed with malignancy at the time of presentation. Awareness of this condition will prompt clinicians to search for underlying malignancies. Any patient with onset of polymorphic oral erosions with clinical and histopathologic findings not pathognomonic for a specific diagnosis should have a detailed history inquiry and complete physical examination (especially viscera roentgenogram).<sup>6</sup>

The two reported patients with PNP initially presented with severe polymorphic erosive oral lesions. Both patients, respectively, had developed oral lesions 2 and 7 months after being diagnosed with underlying malignancy.

Most frequent underlying neoplasm associated with PNP is non-Hodgkin lymphoma, chronic lymphocytic leukemia, thymoma,

Castleman disease, and Waldenström macroglobulinemia.<sup>7</sup> In the present patients, PNP developed secondary to lymphocytic leukemia and thymoma.

**Diagnosis**

The diagnosis of PNP is established by polymorphous mucocutaneous eruption, routine histology, direct and indirect immunofluorescence, and immunoprecipitation studies on keratinocyte extracts. Histologic examination is often routinely performed and is of the same importance. Suprabasal cleft or bullae formation with acantholysis and keratinocyte necrosis, inflammation at the dermal-epidermal junction, or lichenoid infiltrate are primarily found in mucosal and/or cutaneous biopsy specimens. To help in diagnosing PNP, Camisa and Helm proposed a set of diagnostic criteria for PNP (Table 1). Diagnosis of PNP requires three major, or two major and at least two minor, criteria to be fulfilled.<sup>8</sup> Our patients presented two major and three minor criteria, and a final diagnosis of PNP was thus made. Immunoprecipitation test is one of three major criteria. Although sensitive, it is tedious, expensive, and not readily available. In contrast, the indirect immunofluorescence test against rat bladder is simpler and yet relatively sensitive (76%) and specific (83%).<sup>9,10</sup> In the present cases, indirect immunofluorescence on rat bladder, esophagus, and small intestine revealed circulating autoantibodies to epithelial cell surface and basement membrane zone, and it has been shown to be an inexpensive and reliable diagnostic tool.

In our cases, direct immunofluorescence using the patient’s perilesional tissue or pemphigus cytological smear as substrates shows IgG and complement deposition in the intercellular spaces between the keratinocytes and



along the basement membrane.<sup>11</sup> However, direct immunofluorescence result could be equivocal or negative in some patients.<sup>12,13</sup> Therefore, the fact to be stressed is that if PNP is strongly suspected clinically, negative direct immunofluorescence does not completely rule out the possibility of the disease.

### Treatment and prognosis

Due to presence of underlying malignancy, patients with PNP often are unresponsive to routine therapy. Therapy entails management of underlying malignancy as well as high-dose systemic steroids. Other strategies include immunosuppressive therapy with cyclophosphamide, methotrexate, azathioprine, colchicine, and plasmapheresis.

Prognosis of PNP is poor in general. Most patients die either from the effects of the underlying tumor, from respiratory failure due to acantholysis of the respiratory epithelium, or from the severe lesions that do not respond to therapy.<sup>14</sup> Unless the neoplasia is definitely cured, which happens in rare cases, patients with PNP should be under long-term follow-up.

In both patients, after the control of underlying malignancy, oral lesions improved or cleared with corticosteroid therapy. However, they are still under close follow-up, and long-term efficacy is not predictable.

### SUMMARY

Paraneoplastic pemphigus is a rare subset of pemphigus that has an absolute association with underlying malignancies. Polymorphic oral ulcerations can be the sole and characteristic manifestation of the severe disease. Early recognition may prevent delayed diagnosis and inappropriate treatment. Diagnosis of PNP in the present patients was supported by the indirect immunofluorescence test with rat bladder. Based on better control of the neoplasia, patients may benefit from high-dose systemic corticosteroids and/or immunosuppressives.

### ACKNOWLEDGMENTS

We thank Dr Junad Khan and Dr Andrew Young for their help with the revision of this manuscript.

### REFERENCES

1. Anhalt GJ, Kim SC, Stanley JR, et al. Paraneoplastic pemphigus. An autoimmune mucocutaneous disease associated with neoplasia. *N Engl J Med* 1990; 323:1729–1735.
2. Seishima M, Oda M, Oyama Z, et al. Antibody titers to desmogleins 1 and 3 in a patient with paraneoplastic pemphigus associated with follicular dendritic cell sarcoma. *Arch Dermatol* 2004;140:1500–1503.
3. Schoen H, Foedinger D, Derfler K, et al. Immunoapheresis in paraneoplastic pemphigus. *Arch Dermatol* 1998;134:706–710.
4. Bowen GM, Peters NT, Fivenson DP, et al. Lichenoid dermatitis in paraneoplastic pemphigus: A pathogenic trigger of epitope spreading? *Arch Dermatol* 2000;136:652–656.
5. Wang L, Bu D, Yang Y, Chen X, Zhu X. Castleman's tumours and production of autoantibody in paraneoplastic pemphigus. *Lancet* 2004;363:525–531.
6. Allen CM, Camisa C. Paraneoplastic pemphigus: A review of the literature. *Oral Dis* 2000;6:208–214.
7. Younus J, Ahmed AR. The relationship of pemphigus to neoplasia. *J Am Acad Dermatol* 1990;23:498–502.
8. Camisa C, Helm TN. Paraneoplastic pemphigus is a distinct neoplasia-induced autoimmune disease. *Arch Dermatol* 1993;129:883–886.
9. Helou J, Allbritton J, Anhalt GJ. Accuracy of indirect immunofluorescence testing in the diagnosis of paraneoplastic pemphigus. *J Am Acad Dermatol* 1995;32:441–447.
10. Joly P, Richard C, Gilbert D, et al. Sensitivity and specificity of clinical, histologic, and immunologic features in the diagnosis of paraneoplastic pemphigus. *J Am Acad Dermatol* 2000;43:619–626.
11. Nguyen VT, Ndoye A, Bassler KD, et al. Classification, clinical manifestations, and immunopathological mechanisms of the epithelial variant of paraneoplastic autoimmune multiorgan syndrome: A reappraisal of paraneoplastic pemphigus. *Arch Dermatol* 2001;137:193–206.
12. Barnadas MA, Curell R, Alomar A, Gelpí C. Paraneoplastic pemphigus with negative direct immunofluorescence in epidermis or mucosa but positive findings in adnexal structures. *J Cutan Pathol* 2008; 36:34–38.
13. Tilakaratne W, Dissanayake M. Paraneoplastic pemphigus: A case report and review of literature. *Oral Dis* 2005;11:326–329.
14. Rosenkrantz WS. Pemphigus: Current therapy. *Vet Dermatol* 2004;15:90–98.