

# Clinical Investigation for Bilateral Cleft Lip Repair: Modified Functional Bilateral Cleft Lip Cheilorrhaphy

Wan-Shan Li, DDS,\* Jing-Bo Dai, MDS,† Yuan-Gui Li, MDS,‡  
and Shi-Cheng Wei, MD, DDS, PhD§

**Purpose:** To obtain better operative results, a modified functional bilateral cleft lip (BCL) cheilorrhaphy was designed and used on 131 BCL patients to evaluate the clinical effectiveness in this clinical investigation. A new surgical method would be provided for BCL patients.

**Patients and Methods:** Based on the experiences and advantages of the commonly used self-elongation and elongation surgical methods for BCL repair, a new surgical method was designed for BCL patients. During the operation, this modified functional BCL cheilorrhaphy emphasized the operative design, anatomy and reposition of musculus orbicularis oris, management of the maxilla, and reparation of vermilion of the lip. This method was used to repair 131 BCL patients, and the conditions and results of errhysis, swelling, and healing of trespis vulnus were observed and evaluated.

**Results:** This modified functional BCL cheilorrhaphy was used successfully from January 2002 to July 2005 on 131 BCL patients. The wounds of all patients with BCL who joined this study healed very well without any hematoma, infection, or wound decohesion. All of the patients showed symmetric peak of Cupid's bow, obvious philtrum notch, full vermilion of the lip, little scarring, and satisfactory contour. During functional activity, bilateral upper lip was symmetric, coordinated, and balanced.

**Conclusions:** The clinical results showed that modified functional BCL cheilorrhaphy may be accepted as a good selective surgical technique for BCL patients, and is worth generalization and application.

© 2008 American Association of Oral and Maxillofacial Surgeons  
*J Oral Maxillofac Surg* 66:21-28, 2008

Bilateral cleft lip (BCL) is one of the most common congenital deformities in the oral and maxillofacial region. Although the morbidity is much lower, the deformity obviously affects the appearance and func-

tions (such as sucking, speaking, breathing, etc) of patients because of its seriousness. At the same time, the treatment for BCL patients is more complex and difficult than that for unilateral cleft lip patients, especially when a BCL patient is accompanied by a bilateral cleft alveolus and palate. It is hard to achieve good results and the outcome is less acceptable. Multidisciplinary management is an important pathway to improve therapeutic effectiveness,<sup>1-3</sup> but many patients in China cannot accept the multidisciplinary management due to various factors, such as equipment, technique, communication, familial economic status, etc. Surgery is still the primary choice for treatment of BCL patients. Each oral and maxillofacial surgeon faces the challenge of improving the operative effectiveness efficiently. In recent years, a modified functional BCL cheilorrhaphy, which emphasized the operative design, anatomy, and reposition of musculus orbicularis oris, management of the protruding premaxilla, and reconstruction of vermilion, was designed and used in our clinic, and BCL patients have achieved ideal therapeutic effectiveness.

---

\*Associate Professor and Director, Center of Cleft Lip and Palate, Children's Hospital, and Vice Director, Department of Oral and Maxillofacial Surgery, School of Stomatology, Chongqing Medical University, Chongqing, China.

†Resident, Department of Stomatology, Leshan Red Cross Hospital, Leshan, Sichuan, China.

‡Attending Physician, Department of Stomatology, Children's Hospital, Chongqing Medical University, Chongqing, China.

§Professor, Department of Oral and Maxillofacial Surgery, School and Hospital of Stomatology, Peking University, Beijing, China.

Address correspondence and reprint requests to Dr Wei: Department of Oral and Maxillofacial Surgery, School and Hospital of Stomatology, 22 South Avenue, Zhongguancun, Haidian District, 100081, Beijing, P.R. China; e-mail: kqsc-wei@bjmu.edu.cn

© 2008 American Association of Oral and Maxillofacial Surgeons  
0278-2391/08/6601-0005\$34.00/0  
doi:10.1016/j.joms.2007.05.027

## Patients and Methods

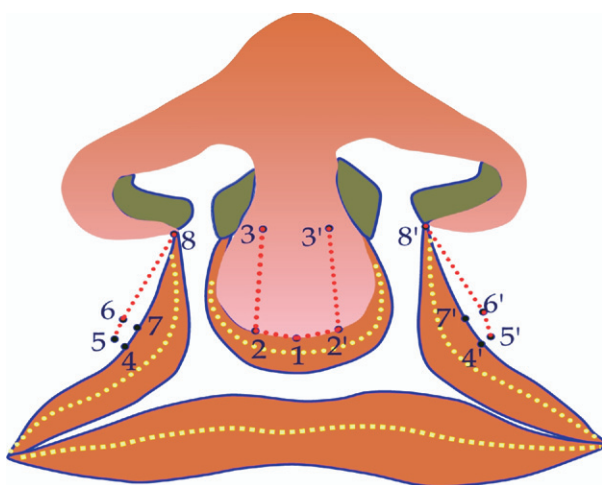
The clinical study for BCL patients with a newly designed surgical technique, modified functional BCL cheilorrhaphy, to repair BCL, occurred from January 2002 to July 2005. The number of involved BCL patients admitted by our department was 131, and comprised bilateral incomplete cleft lip ( $n = 54$ ), bilateral complete cleft lip ( $n = 70$ ), and bilateral mixed cleft lip ( $n = 7$ ). Of all patients, 98 BCL patients were accompanied with cleft palate and 53 with obviously protuberant premaxilla. There were 93 male patients and 38 female patients aged from 2.06 months to 14.98 years, average 2.09 years; 16 patients were younger than 3 months; 37 patients ranged from 3 to 6 months; 38 patients ranged from 6 to 12 months; 40 patients were older than 1 year. All patients came from rural areas and received no other related treatments before operation.

### SURGICAL TECHNIQUE

The operative procedures are performed under general anesthesia using endotracheal intubation. After satisfactory induction of anesthesia and placement of a conformed oral endotracheal tube fixed on the chin in the midline, the patient is placed in the supine position with the neck slightly extended using a small shoulder roll. The operating table is tilted into a slight reverse Trendelenburg position. The face is prepared and draped, and sterile tapes are placed over the closed eyelids.

### OPERATIVE DESIGN

The mark points are shown in Figure 1. The specific mark points of anterior and lateral lips are described as follows, respectively.



**FIGURE 1.** Key landmarks and surgical plan outlined with pen and gentian violet ink.

Li et al. *BCL Cheilorrhaphy*. *J Oral Maxillofac Surg* 2008.

### Anterior Lip

Point 1, the philtral notch of the anterior lip, is marked on the anterior lip midpoint at the vermilion-cutaneous junction. Points 2 and 2', the peaks of the Cupid's bow at the anterior lip, are at the vermilion-cutaneous junction, which is located at the 2 sides of point 1, and is 2 to 3 mm from point 1. The lengths of line 1-2 and line 1-2' are equal ( $L_{1-2} = L_{1-2'}$ ), and the lengths are related to the ages of the patients; they are longer in older patients and shorter in younger patients. Points 3 and 3' are drawn at the lip-columellar crease, and are located at the slightly lateral side of nasal columellar base. Postoperatively, in order to ensure the lower part of the upper lip is wider than the upper part, the width of 3-3' should be shorter than that of 2-2'. Lines 1-2-3, 1-2'-3' are connected, respectively. After the operation, lines 2-3 and 2'-3' will form the superior part of bilateral philtral column, respectively.

### Lateral Lip

Points 4 and 4', the peaks of the Cupid's bow of the bilateral lateral lips, are respectively positioned along the vermilion-cutaneous junction at the point where the cutaneous roll and red line (vermilion-mucosal junction) begin to converge medially,<sup>4</sup> and the distance of point 4 to the right angle of mouth is equal to that of point 4' to left labial commissure. Along the lines perpendicular to the vermilion-cutaneous junction and passing through point 4 and point 4', point 5 and point 5' are marked just above the cutaneous roll, respectively; and the lengths of line 4-5 and line 4'-5' are 1 cm. Point 6 is located on the medial superior part of point 5, and it is 2 mm from the vermilion-cutaneous junction and intersects with the vermilion-cutaneous junction at point 7. Line 5-6 and line 1-2 will meet together after the operation, so their lengths are equal ( $L_{5-6} = L_{1-2}$ ). Using the same method, points 5', 6', and 7' are marked, respectively, on the other side of lateral lip, and make the lengths of line 5'-6' and line 1-2' equal ( $L_{5'-6'} = L_{1-2'}$ ). The points of proposed closure in the bilateral nostril sill (point 8 and point 8') are then positioned on nasal basal line (a line connected bilateral nasal alar base). Ultimately, the positions of point 8 and point 8' should be positioned relative to point 3 and point 3', respectively, such that when point 8 and point 3 are approximated, point 8' and point 3' meet together, respectively, after the operation. The width of the bilateral nasal base (sum of distances of point 8 to nasal alar base of same side and point 3 to nasal columellar base of same side, sum of distances of point 8' to nasal alar base of same side and point 3' to nasal columellar base of same side) will be equal, and the alar bases will lie in the same vertical level. A lateral rhinotomy incision along the alar crease is

unnecessary and never used, otherwise it will leave an unsightly scar. Line 5-6-8 and line 5'-6'-8' are connected respectively. Postoperatively, line 6-8 and line 2-3 will meet together, so the lengths of line 6-8 and line 2-3 are equal ( $L_{6-8} = L_{2-3}$ ). Therefore, the lengths of line 6'-8' and line 2'-3' are equal ( $L_{6'-8'} = L_{2'-3'}$ ). The red line<sup>4</sup> (boundary of wet and dry lips) is marked on the vermilion of the bilateral lateral lip from the angle of mouth to the end of cleft or the nasal base of cleft.

#### INCISION

Key landmarks are tattooed with gentian violet dye and a 25-gauge needle. Bilateral infraorbital nerve blocks are performed, and the bilateral alar base, piriform rim, anterior lip, and inferior turbinate are infiltrated with 1% lidocaine with epinephrine (1:200,000); no infiltration of the bilateral lateral lips is performed. After placement of a moist mouth pack, incision begins with scalpel and scissors, which includes dissection of anterior lip and bilateral lateral lips, and dissection of musculus orbicularis oris. The specific steps follow.

The opening incision for the anterior lip is through skin and subcutaneous tissue along the lines 1-2, 2-3, 1-2' and 2'-3'. Cleft marginal tissue is discarded. Carefully dissect up along the periosteous surfaces of the premaxilla and elevate the flap of the anterior lip to the cartilage of the nasal septum, and then completely stop the bleeding. Enucleate and modify the redundant oral mucosa of bilateral edges of the anterior lip and make it a triangular tissue flap that is convenient for appositional suture with oral mucosa of bilateral lateral lips.

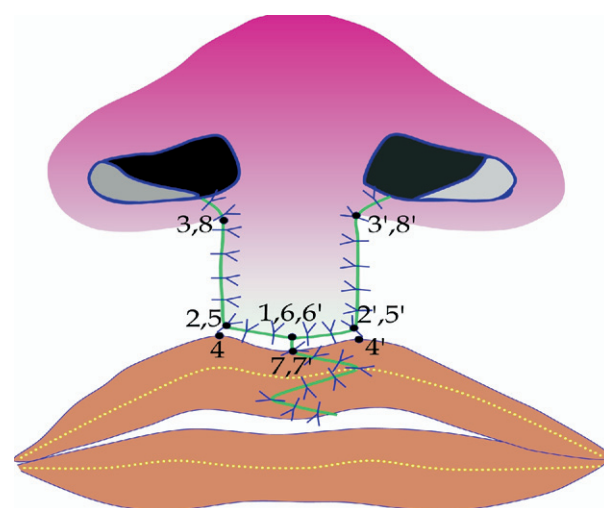
In the bilateral lateral lip regions, a full-thickness incision is carefully and correctly made along the line 5-6-8 and line 5'-6'-8', respectively. When incising, in order to ensure that the mucomuscular flap of vermilion has some thickness, the knife point should be oriented laterally slightly. And then a sharp dissection is made along the incisions, and frees the orbicularis oris muscle from the overlying skin and the underlying mucosa. At the same time, the dissection between skin and muscle is more extensive, extending laterally as far as the alar base to relieve the orbicularis oris muscle bulge. Orbicularis is freed from its upturned insertion in the region of the alar base and the alveolar cleft margin, and is repositioned; simultaneously, the alar base is also freed from the underlying maxilla after the dissection is made deep to muscle and in an extraperiosteal plane. The nasal vestibular web, formed by the caudal margin of the lower lateral cartilage's lateral crus, the accessory cartilages, and investing perichondrium, is released from its posterolateral attachment to the piriform rim. When this release from the piriform rim is sufficient, the alar base can now be advanced anteromedially without

accentuating the buckling of the alar rim and the lateral alar flare. If there is significant anteroposterior distance between the medial and lateral maxillary segments, anteromedial advancement of the alar base will leave a large raw periosteal surface at the upper alveolus and lower piriform margin that is best covered with the buccal composite tissue flap. A relaxed incision at the switch region of mucosa with bilateral or unilateral vestibular groove was made for the patients with complete or mixed BCL, and ended on the surfaces of periosteum, stripped widely to relieve strains and cover the raw surface.

#### SUTURE

Suture of BCL is shown in Figure 2. It includes reconstruction of basis nasal defects, suture of oral mucosa, and reposition of musculus orbicularis oris and closure of skins. Presently, we use 3-0 silk for the oral mucosa; 0 or 3-0 silk for relaxed incision of vestibular groove, 3-0 Vicryl plus antibacterial suture (polyglactin 910 undyed braided absorbable suture) for muscle approximation; 5-0 Vicryl rapide suture for alar transfixion sutures; 5-0 silk for skin and vermilion.

For the patients with complete or mixed BCL, the basis nasal defects should be closed and reconstructed with the tile-like flap or turn-over flap; turn-over flaps were often used in our clinic. After the repair for the oral side of the defects is finished, an eye scissor is used to free the nasal alar cartilage from the overlying skin and the underlying mucosa, and is extended from the ala base to the nasal tip. The closure continues caudally with the approximation of the medial and lateral lip element mucosa by appositionally suturing the oral mucosa of the bilateral lateral lips and oral mucosa flap of the anterior lip, which was clipped to be a triangle. The upper buccal



**FIGURE 2.** Incision suture after operation.

sulcus relaxed incision is sutured and closed. From within the nasal vestibule, forceps are used to reposition the lateral domes anteromedially and to grasp the caudal margin of the upper lateral cartilage. One or 2 internal nasal valve plication sutures are placed to maintain the anteromedial advancement of the lateral crus and to create the normal overlap of the lower lateral cartilage and the upper lateral cartilage. The columellar base and alar base of the lateral lips are approximated with an "alar cinch stitch." Careful placement of this suture will allow the alar bases and columellar base to be positioned in the appropriate horizontal plane. Next, reconstruct the bilateral musculus orbicularis oris by making it horizontally repositioned and firmly suture on the surface of premaxilla, which had been amply separated, and cut down its abnormal muscular insertion located on the bilateral nasal alar base, and recover its continuity. Tractate the tissue flaps of the bilateral vermilion of the lip down and place the points 5, 2, 5', and 2' to the same horizontal position, and appositionally suture the points 7 and 7', points 5 and 2, points 5' and 2', points 6, 6', and 1, and close the bilateral skin incision upward with simple interrupted sutures. New philtral notch is formed by suturing points 7 and 7'. Now the reparation of the upper parts of the upper lip is completed.

#### REPARATION OF VERMILION

Repair of the vermilion is shown in [Figure 2](#). In the thin and narrow side of the vermilion, an opening incision is made along the "red line" from the philtral notch. Draft the terminal down and form a triangle mucomuscular flap of wet vermilion, whose pedicle is located below. While in the broad and thick side of the vermilion, a triangular musculomucosal flap is formed, whose pedicle is located above. The flap is debulked of underlying muscle, trimmed to size, and inserted into the opening incision along the red line in the thin and narrow side of the vermilion. Appositional suture is performed under the condition that the red line is continuous. Then the reparation of vermilion is completed.

#### MANAGEMENT AND OBSERVATION AFTER OPERATION

After operation, the throat pack and eyelid tapes are removed, and yarn pads with Iodophors are placed onto the wounds and fixed with waterproof sticking plaster. The patient is awakened from general anesthesia and extubated. Labial arch appliance is not routinely used. Carefully observe errhysis, swelling, and healing of the trespis vulnus. Patients are given routine anti-inflammatory and antioncotic treatment, and the wounds are kept sanitary. Remove the yarn pads the next day, and remove the lip sutures at the

seventh day after the cheiloplasty. Evaluate their clinical effectiveness, which includes contour of the peak of the Cupid's bow, philtral notch, vermilion and nasal columella, etc, and function of upper lip. In order to evaluate the scars from the lip wound, routine return visits are performed 3 weeks postoperatively. If necessary, prophylactic injection for scars should be adopted with triamcinolone acetonide.

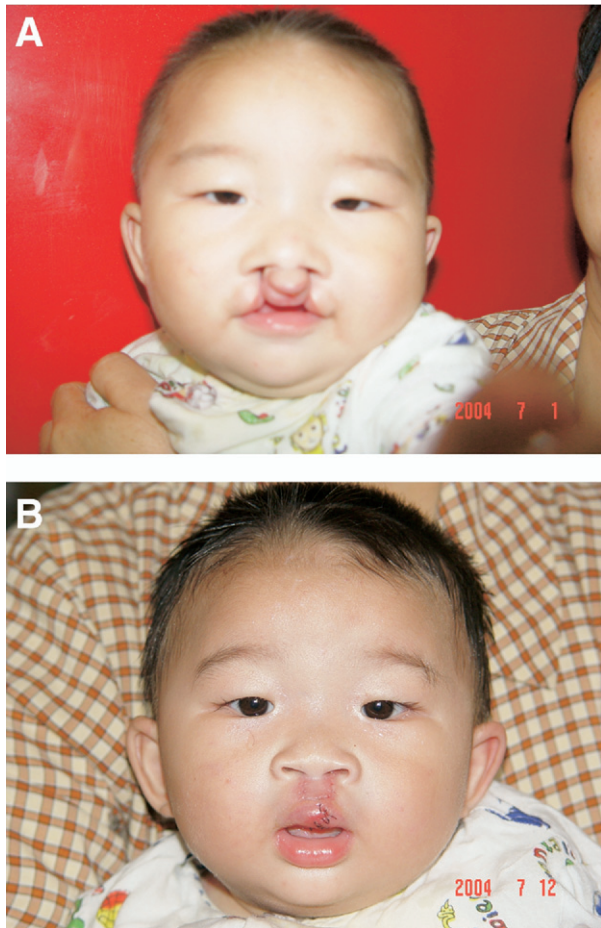
## Results

After the operation, various degrees of swelling occurred in all patients and subsided in 2 to 3 days. No local hematoma was formed; we normally remove the suture lines at the seventh day postoperatively without any infection and wound decohesion. Wounds of patients healed very well with symmetric peak of Cupid's bow, obvious philtral notch, full vermilion of the lip, little scarring, satisfactory contour and no whistling deformities, and "trivalve mouth," etc. During functional activity, bilateral upper lip was symmetric, continuous, coordinated, and balanced without separations in middle parts. Bilateral nose was symmetric but nasal columella was small and short. The upper lip of patients with obvious extrusive premaxilla was tight shortly after the operation. Among these patients, the repair effectiveness of patients with complete BCL, incomplete BCL, and mixed BCL before and after operation are shown in [Figures 3 through 6](#).

## Discussion

BCL is a congenital deformity that severely affects the contours and functions of patients. Surgery is the only way to cure it up to now. But the problems of surgical treatment for patients are complex and controversial.

Various techniques have been reported and described in detail. According to the frequencies of surgery, they include staged closure<sup>1,5-7</sup> and simultaneous closure of both sides,<sup>1,8,9</sup> and simultaneous closure is the common practice in China. On the other hand, due to the difference of the surgical methods, in that the prolabium was used for reconstruction of upper lip, Adams et al<sup>10</sup> summarized 2 kinds of reconstructive methods for BCL, which are self-longation method<sup>6,11,12</sup> and elongation method.<sup>1,13</sup> As for the self-longation method, there are differences in surgical techniques. Straight-line closure<sup>11</sup> has been used, along with other techniques, among which the rotation-advancement technique<sup>12</sup> and the triangular flap<sup>6</sup> repair based on Tension's design<sup>14</sup> are popular; during operation, the entire prolabium is used to reconstruct the midportion of upper lip, and the margins of the Cupid's bow of the anterior lip remains; but after the operation,



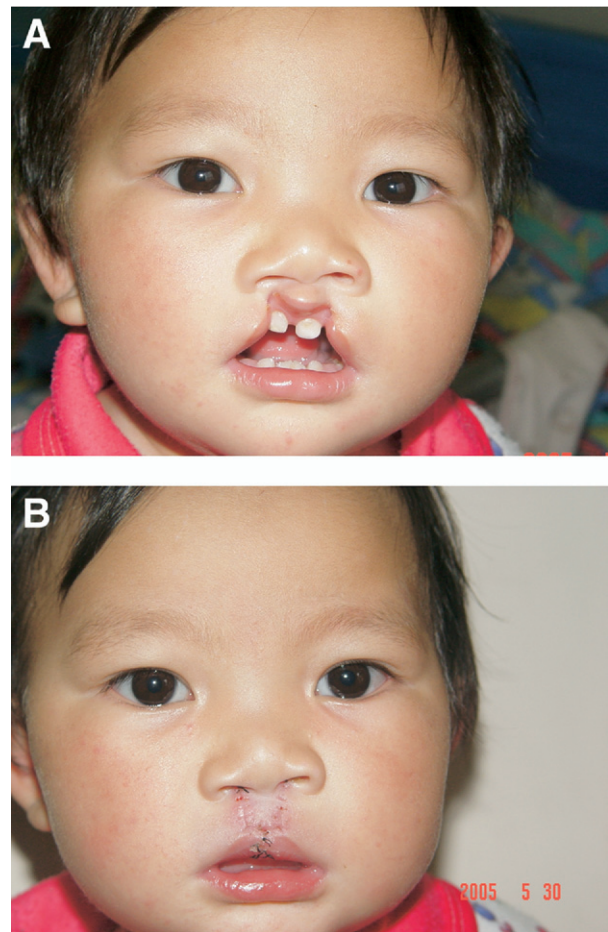
**FIGURE 3.** A, Preoperation (complete BCL). B, One week after operation (complete BCL).

*Li et al. BCL Cheilorrhaphy. J Oral Maxillofac Surg 2008.*

many shortcomings will occur including unsharp middle parts of the Cupid's bow, indistinct vermilion-cutaneous junction, flat and indistinct peak of Cupid's bow. For the elongation method, the prolabium is used to reconstruct the middle and upper portions of the upper lip, and the lateral lip elements are used to reconstruct the vermilion and lower portions of the upper lip below the prolabium. The length of the anterior lip is extended by using lateral lip tissues, but obvious sequel deformities will exist in most patients subsequently, including obvious swelling appearing as a white button-like island due to severe inhibition of growth of anterior lip, tight upper lip that is obviously artificial because of extra loss of side lip tissues, over-length of the anterior lip with disproportion, excessive and distinct scars in the middle and lower parts of the anterior lip, and vermilion tissues with introcession and defects. The novel method described in this article fully integrated the advantages of these 2 kinds of methods. After operation, the Cupid's bow of the anterior lip is formed by natural Cupid's bow of bilateral lateral lips, the achieved Cupid's bow looks

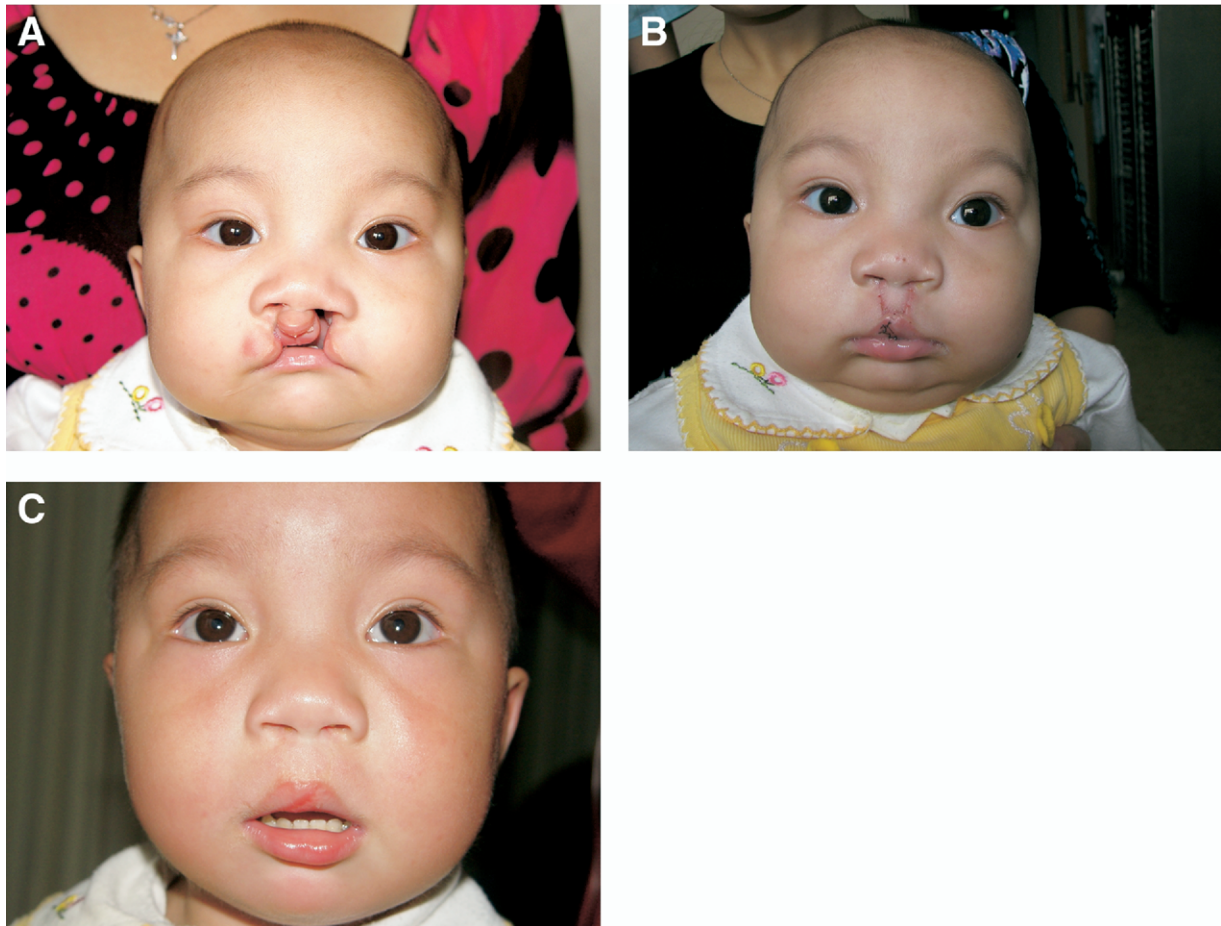obvious and distinct; and the philtral notch (7 and 7') is lower than the peak of the Cupid's bow (4 and 4') by more than 1 mm (4-5 = 1 mm, 6-7 = 2 mm), which is consistent with the structure and appearance of upper lip in normal persons. Simultaneously, the width of tissues flap of bilateral lateral lip incised is only 1.0 to 2.0 mm, so it will not cause tight upper lip postoperatively. This method also overcomes the disadvantages of these 2 kinds of methods. One hundred thirty-one BCL patients were treated with this method and satisfactory clinical results were achieved postoperatively, which fully proved the advantages of this method.

Functional cleft lip repair was raised by Delaire<sup>15</sup> in 1978; the reconstruction of musculus orbicularis oris and good closure for muscles and skins were emphasized in operation. In normal upper lip, Briedis et al<sup>16</sup> reported that the orbicularis oris exists in 2 layers, a deep layer that is continuous across the midline and a superficial layer that interdigitates in the midline beneath the philtrum and gains insertion into the dermis lateral to each contralateral philtral ridge. But in the



**FIGURE 4.** A, Preoperation (incomplete BCL). B, One week after operation (incomplete BCL).

*Li et al. BCL Cheilorrhaphy. J Oral Maxillofac Surg 2008.*



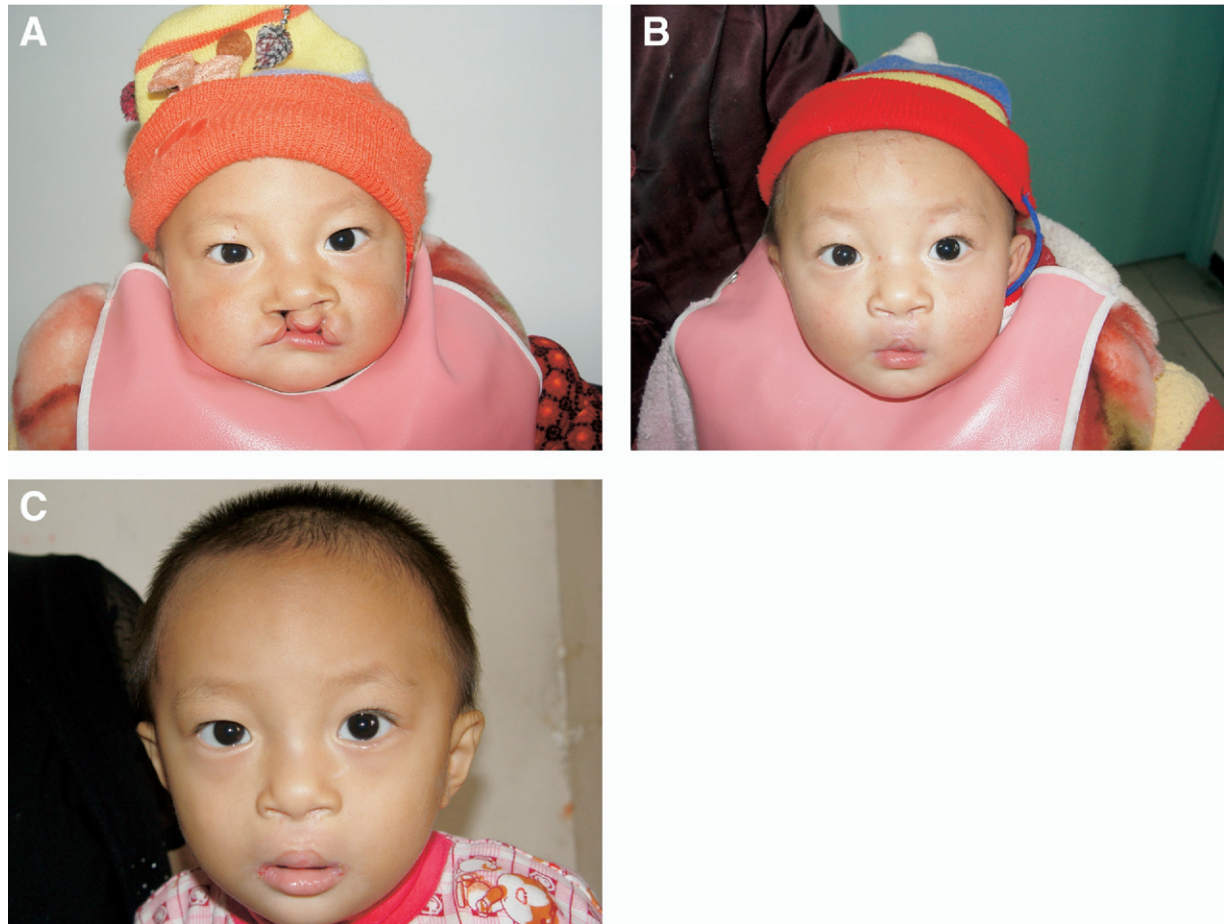**FIGURE 5.** A, Preoperation (mixed BCL: left complete cleft lip and right incomplete cleft lip). B, One week after operation (mixed BCL: left complete cleft lip and right incomplete cleft lip). C, 1.4 years after operation (mixed BCL: left complete cleft lip and right incomplete cleft lip).

*Li et al. BCL Cheilorrhaphy. J Oral Maxillofac Surg 2008.*

complete BCL, Fara<sup>17</sup> found the orbicularis oris muscle running along the edge of the cleft, turning toward the alar base, and adhering into nasal ala base, periosteum of piriform aperture and vicinal skins, and the prolabium is devoid of muscle fibers. In the incomplete BCL, sparse orbicularis oris muscle fibers with variant ultrastructures can pass through the bridge, and enter and fill the prolabium. Even if the straight line method was adopted, the anterior lip of patients only included sparse muscle fibers with variant ultrastructures that proliferated from the lateral lips.<sup>18</sup> In China, most surgeons will perform operations with the orbicularis oris muscle of the upper lip not dissected and repositioned. In these operations the muscle fibers were discontinuous, so the upper lip was mismatched due to abnormal attachment of muscle during functional activity postoperatively; simultaneously, nasal deformities were aggravated and muscle eminences of bilateral lateral lips were formed. In our research, sharp separation was performed on bilateral lateral lips from the nasolabial groove and musculus orbicularis oris, which was lo-

cated in nasal ala base, was amply liberated and divided from the abnormal insertion, and made completely repositioned and end-to-end apposition suture on the surfaces of premaxilla. Musculus orbicularis oris band with good functions was achieved. During the operation, elevate the anterior lip flap to fully isolate the end of the nasal columella and decrease the tensile force of skins of the anterior lip to the nasal columellar base. At the same time, lengthen the anterior lip by cutting down bilateral lateral lip tissues 1 to 2 mm in length, and the condition of short and small nasal columella will be improved. Moreover, complications such as hematoma never occurred postoperatively.

Cheilorrhaphy of BCL involves the management of the premaxilla. BCL patients, especially with complete BCL, are often accompanied with bilateral cleft alveolus and/or palate, and the premaxilla is only attached to the nasal septum by septomaxillary ligament and may be rotated upward and forward because it is unrestrained by the upper lip and maxillary alveoli; the premaxilla is often protruded and dis-



**FIGURE 6.** A, Preoperation (mixed BCL: left incomplete cleft lip and right complete cleft lip). B, One week after operation (mixed BCL: left incomplete cleft lip and right complete cleft lip). C, 1.5 years after operation (mixed BCL: left incomplete cleft lip and right complete cleft lip).

Li et al. BCL Cheilorrhaphy. *J Oral Maxillofac Surg* 2008.

placed.<sup>19,20</sup> In some patients, the premaxilla even contacted with the nasal tip, and the nasal columella may disappear, then high strain will be produced during the operation; complications such as wound decohesion would occur postoperatively. It was important to correctly solve the problem of the protrusive premaxilla. We do not advocate forceful manipulation of the premaxilla before cleft lip repair. Applying pressure to the protruding premaxilla results in deviation of the nasal septum, which may become severe and in many cases force the premaxilla downward.<sup>1</sup> Retropositioning of the premaxilla cannot be compared to excision of the premaxilla, which is totally unacceptable even in the most severe cases of premaxillary protrusion. Partial or total excision of the premaxilla severely affects anteroposterior facial growth, whereas premaxillary recession has no detrimental effect.<sup>1</sup> Although presurgical orthodontic treatment results in retropositioning of the premaxilla within the alveolar arch and establishes a satisfactory occlusal relationship,<sup>1,21,22</sup> more time and more money will be expended. According to our experi-

ences, after the cartilago nasi lateralis and buccal tissues are completely freed from the loose incision of the bilateral vestibular groove, and orbicularis oris muscle fully separated and cut down from the abnormal attachment, bilateral musculus orbicularis oris could be sutured smoothly without obvious strain, and the lateral crura of ala nasi could also be placed to the normal position. Postoperatively, we also didn't use the labial arch by reliving stain, and wound decohesion didn't occur in our patients.

Repair of vermilion has attracted wide attention from surgeons. The result that "a good aspect makes those bad ones be ignored" would be achieved if appropriate management was taken. The peak of the Cupid's bow and the vermilion tubercle of BCL patients were absent with thin vermilion. In order to make the contour of the vermilion abundant, symmetric and natural, and the labial tubercle obvious, we reconstructed the Cupid's bow of the anterior lip using the rim of the Cupid's bow of the bilateral lateral lips. After the operation, the Cupid's bow was comprised with bilateral natural Cupid's bow, so the

peak of the Cupid's bow and the philtral notch were distinct and sharp. Simultaneously, a thick and long vermilion flap was formed by making the knife point inclined outward when incising the bilateral lateral lips, and then displaced, crossed, and sutured under the lower parts of the anterior lip, and abundant vermilion tubercle was formed. In addition, in order to avoid wet and dry lip of vermilion mixing, vermilion flaps formed in operation should be incised from the boundary of wet and dry lips, and then the boundary of wet and dry lip of vermilion was distinct, continuous, and natural.

Functional cheilorrhaphy for BCL patients was applied with marked points of anterior and lateral lip, anatomy and reposition of musculus orbicularis oris, good management of premaxilla and reparation of vermilion of lip and significant effectiveness is achieved postoperatively. So this method can be selectively applied to reparation for BCL patients, especially completely BCL patients.

## References

- Bardach J, Salyer KE, Noordhoff MS: Bilateral cleft lip repair. in Salyer KE, Bardach J (eds): Salyer & Bardach's Atlas of Craniofacial & Cleft Surgery, Volume II: Cleft Lip and Palate Surgery. Lippincott Williams & Wilkins, 1999, pp 113-172
- Pdawa BL, Mulliken JB: Sequential management of the child with cleft lip and palate, in Kaban LB, Troulis MJ (eds): Pediatric Oral and Maxillofacial Surgery. W.B. Saunders Company, 2004, pp 410-425
- Schnitt DE, Agir H, David DJ: From birth to maturity: A group of patients who have completed their protocol management. Part I. Unilateral cleft lip and palate. *Plast Reconstr Surg* 113: 805, 2004
- Noordhoff MS: Reconstruction of vermilion in unilateral and bilateral cleft lips. *Plast Reconstr Surg* 73:52, 1984
- Cronin TD: Surgery of the double cleft lip and protruding premaxilla. *Plast Reconstr Surg* 19:389, 1957
- Bauer TB, Trusler HM, Tondra JM: Changing concepts in the management of bilateral cleft lip deformities. *Plast Reconstr Surg* 24:321, 1959
- Skoog T: Skoog's methods of repair of unilateral and bilateral cleft lip, in Grabb WC, Rosenstein SW, Bzoch KR (eds): Cleft Lip and Palate. Boston, Little, Brown & Co, 1971, pp 288-304
- Manchester WM: A method of primary double cleft lip repair. in Hueston JT (ed): Transactions of the Fifth International Congress of Plastic and Reconstructive Surgery. Melbourne, Butterworths & Co Ltd, 1971, pp 193-206
- Broadbent TR, Woolf RM: Bilateral cleft lip: One-stage primary repair, in Georgiade NG, Hagerty (eds): Symposium on Management of Cleft Lip and Palate and Associated Deformities. St Louis, CV Mosby Co, 1974, pp 134-138
- Adams WM, Adams LH: The misuse of the prolabium in the repair of bilateral cleft lip. *Plast Reconstr Surg* 12:225, 1953
- Glover DM, Newcomb MR: Bilateral cleft lip repair and the floating premaxilla. *Plast Reconstr Surg* 28:365, 1961
- Millard DR: Bilateral cleft lip and a primary forked flap: A preliminary report. *Plast Reconstr Surg* 39:59, 1967
- Jiawei Z, Xingyun S, Peihui Z, et al: Modified bilateral cleft lip repair with orbicularis reconstruction and prolabial self-elongation. *J Oral Maxillofac Surg* 56:28, 1998
- Tennison CW: The repair of the unilateral cleft lip by the stencil method. *Plast Reconstr Surg* 9:115, 1952
- Delaire J: Theoretical principles and technique of functional closure of the lip and nasal aperture. *J Maxillofac Surg* 6:109, 1978
- Briedis J, Jackson IT: The anatomy of the philtrum: Observations made on dissections in the normal lip. *Br J Plast Surg* 34: 128, 1981
- Fara M: Anatomy and arteriography of cleft lips in stillborn children. *Plast Reconstr Surg* 42:29, 1968
- Zheng HP, Zhao HQ, Zheng JW, etc: A study on anatomy and structure of bilateral cleft lip. *Chinese Journal of Medical Aesthetics and Cosmetology* 5:10, 1999
- Latham RA: Development and structure of the premaxillary deformity in bilateral cleft lip and palate. *Br J Plast Surg* 26:1, 1973
- Heidbuchel KL, Kuijpers-Jagtman AM, Freihofer HP: An orthodontic and cephalometric study on the results of the combined surgical-orthodontic approach of the protruded premaxilla in bilateral clefts. *J Craniomaxillofac Surg* 21:60, 1993
- Grayson BH, Cutting CB: Presurgical nasolabial orthopedic molding in primary correction of the nose, lip, and alveolus of infants born with unilateral and bilateral clefts. *Cleft Palate Craniofac J* 38:193, 2001
- Berkowitz S, Mejia M, Bystrick A: A comparison of the effects of the Latham-Millard Procedure with those of a conservative treatment approach for dental occlusion and facial aesthetics in unilateral and bilateral complete cleft lip and palate: Part I. Dental occlusion. *Plast Reconstr Surg* 113:1, 2004